ISSN: 2634 - 6796

Journal of Cardiology Research Reviews & Reports

SCIENTIFIC Research and Community

Case Report

Open Access

Bifurcation Lesion of a Y-shaped Saphenous Vein Graft Treated Via Mini-Crush Technique

Inanc Artac*, Muammer Karakayali, Timor Omar, Dogan Ilis, Ayca Arslan, Ezgi Guzel, Mehmet Hakan Şahin, Yavuz karabag and Ibrahim Rencuzogullari

Assistant Professor, Kafkas University Faculty of Medicine Department of Cardiology kars, Turkey

***Corresponding author**
Inanc Artac, Assistant Professor, Kafkas University Faculty of Medicine Department of Cardiology Kars, Turkey.

Received: January 25, 2024; **Accepted:** January 30, 2024; **Published:** February 23, 2024

Original Case Report

Presentation

A 77-year-old female patient presented in ER with progressing ischemic chest pain for last 3 days. Electrocardiogram (ECG) was sinus rhythm with minimal ST-depression in leads D1, aVL, V5 and V6. Patient had diabetes, hypertension, hyperlipidemia and coronary artery bypass graft surgery that performed 10 years ago. Her first cardiac troponin level was 68 ng/L at admission and the control cardiac troponin result was 450 ng/L three hours later (cut-off 0.01-0.04). D-dimer and creatinine levels were normal. Saturation was 94% in room air at pulse oximetry and blood pressure was 140/80 mmHg. Bedside echocardiography revealed an ejection fraction of 45-50% with septal and lateral wall hypokinesia, and 1-2 mitral valve regurgitation. Patient admitted in coronary intensive care unit with the diagnosis of myocardial infarction with non-ST elevation. After treatment with 5000 IU intravenous unfractionated heparin and 300 mgr acetylsalicylic acid, the patient was transferred to the catheterization laboratory. Coronary angiography was performed via the right femoral artery and revealed a total occlusion of the native left anterior descending, right coronary artery and Optus margin1 (OM1). Additionally, patent LIMA to LAD bypass and critical bifurcation stenosis in the Y-graft to the diagonal-1 and OM1 arteries was observed (Figure 1). The decision was made to treat the lesion of the venous graft as treat in the native coronary arteries. Given the degree of atherosclerosis involving both branches of the Y-shaped venous graft, a stenting technique fully covering the bifurcation segment of the graft was considered, the "mini-crush" technique with the use of paclitaxel-eluting stents, was selected. Before beginning the procedure, intracoronary clonitap (10 mgr) and ticagrelor 180 mgr. p.o was applied and the lesions was wired with a floppy (workhorse) guidewire (Asahi Intecc Medical); and the venous graft branch supplying the D1 was considered as the main branch. Following the steps of the "mini-crush" technique as described before, a 3.0 × 20 mm paclitaxel-eluting stent was used for the side branch while a 3.5 × 24 mm stent was used for the main branch (Figure 2). After the final POT the procedure was completed with a TIMI 3 flow pattern in both branches (Figure 3). Generally, the use of embolic protection devices were suggested for interventions performed in SVG; however, this option was not available in our catheterization laboratory when the procedure was performed. The patient was discharged home two days after the procedure without any complication. 3 months after discharge, the patient was hospitalized for RCA-CTO revascularization. Coronary angiogram was performed and SVG stents was seen intact with satisfactory findings with a TIMI 3 flow [1-3].

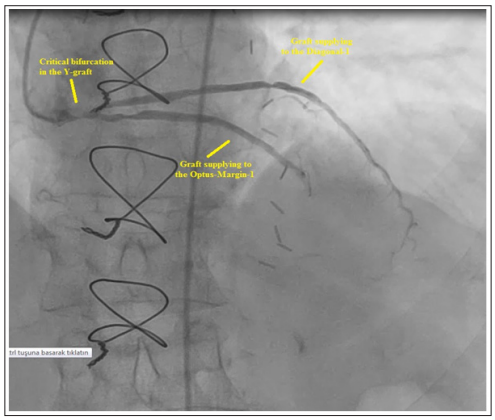

Figure 1: Angiogram showing the Y-shaped saphenous venous graft

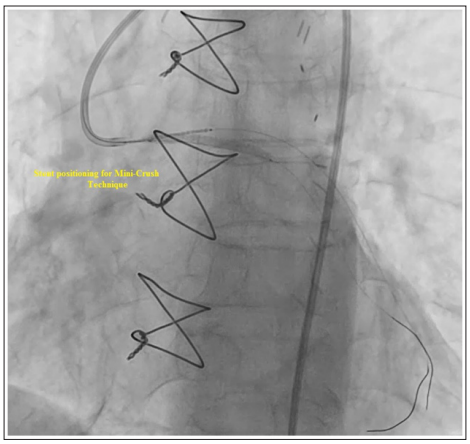

Figure 2: The stents was positioned to cover the hazy lesions proximal to the Y-shaped graft, extending from Diagonal-1 to Optus Margin-1

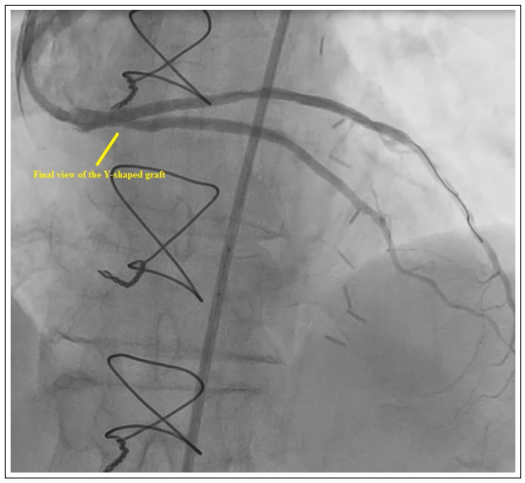

Figure 3: Final view of the graft after recanalization

Discussion

In our case, a substantial angiographic result was achieved. No periprocedural complication has been recorded. Despite the fact that we cannot use a distal protection, a final TIMI flow 3 was reached. The case is unique in the literature since this type of Y-shaped venous graft is rarely used in CABG operations.

Successful percutaneous intervention has been reported for Y-graft bifurcation lesions with the Crush technique and simultaneous kissing stent technique. However, we applied mini-crush technique in our case. In mini-crush technique before SB crushing, the SB stent was minimally retracted to the MB to avoid excessive overlap of metal struts in the proximal MB. Crushing of the SB stent was performed with an MB stent or balloon. For stent optimization, FKB was routinely attempted, and final POT was performed. The main advantages of mini-crush, an up-front 2-stent technique, was associated with a lower occurrence of MACE compared with other PCI bifurcation techniques. Additionally, mini-crush technique gives the operator a shorter and simpler procedure with fewer steps and complete ostial coverage of SB.

In conclusion, the present case demonstrated that the application of the mini-crush stent technique for saphenous vein Y-graft bifurcation lesion with acute coronary syndrome is feasible, and achieving a satisfactory angiographic result with a favorable mid-term clinical outcome.

Acknowledgement

None.

References

1. Iakovou I, Lei Ge, Antonio Colombo (2005) Contemporary stent treatment of coronary bifurcations. J Am Coll Cardiol 46: 1446-1455.
2. Piana RN, Paik GY, Moscucci M, Cohen DJ, Gibson CM, et al. (1994) Incidence and treatment of 'no-reflow' after percutaneous coronary intervention. Circulation 89: 2514-2518.
3. Raphael CE, O'Kane PD, Johnson TW, Prasad A, Gulati R, et al. (2021) Evolution of the Crush Technique for Bifurcation Stenting. JACC Cardiovasc Interv 14: 2315-2326.

Copyright: ©2024 Inanc Artac, et al. This is an open-access article distributed under the terms of the Creative Commons Attribution License, which permits unrestricted use, distribution, and reproduction in any medium, provided the original author and source are credited.