

Case Report
Open Access

Spatial Guidelines in Systemic Restoration of Teeth: Case Report

Serhiy Radlinsky

Apollonia Dental Clinic-Studio, Poltava, Ukraine

ABSTRACT

In the systematic restoration of teeth, it is important to have reliable spatial guidelines, which can be used to reproduce the original anatomical shape of the teeth. Restoring the dentition and bite in the primary vertical dimensions and movements, normalizing the occlusion and balance of the chewing muscles, optimizing the position of the heads in the joints and posture will follow the correct restoration of the anatomical shape of teeth according to a certain system algorithm.

In the direct restoration of teeth in a free hand technique, the leading spatial guidelines are the size and shape of the tooth crown, the outer surface of the preserved enamel, the cervix of the tooth, the topography of the dental tissues (dentinoenamel junction and tooth cavity).

In indirect restoration, there are no specific spatial guidelines in teeth that prepared for fixed prostheses, therefore, for laboratory modeling of teeth and bite, the leading spatial guidelines are the position of the heads in the joints and the movements of the lower jaw with the modeling of the teeth in the articulator.

For both approaches in determining the bite (due to the anatomical shape of the teeth and the position of the lower jaw), the result should be a functional occlusion with all its inherent features.

*Corresponding author

Serhiy Radlinsky, Apollonia Dental Clinic-Studio, Poltava, Ukraine

Received: November 27, 2023; **Accepted:** December 02, 2023; **Published:** December 13, 2023

Keywords: Modeling of Teeth Using Composite, Determination of Bite in the Articulator, Wax Modeling, Spatial Guidelines in Free Hand Restoration

Teeth with the correct anatomical shape are primary and the bite is a secondary, because it formed by the teeth. So secondary functional-anatomic one's formations are the position of the articular heads in the temporomandibular joints, the balance of chewing muscles and the posture, balanced body position.

Loss of dental tissues and teeth due to pathology leads to a violation of the bite, joints, muscle balance and posture, and thus recovery dental tissues and teeth in the primary anatomical form normalizes all secondary functional anatomical formations.

Thus, the so-called bite height, or vertical dimension of occlusion (VDO), is formed secondarily and is determined occurs when the upper and lower posterior teeth with the primary anatomical shape are in contact with each other support them cusps. That is, to find the initial bite height must be returned to the lost anatomical shape of supporting teeth, and then the rest of the process hidden functional and anatomical formations will be found automatically!

Spatial Guidelines of the Lost Anatomical Teeth Shape

To restore the lost anatomical shape, it was not enough to know and repeat the typical elements of the teeth anatomical shape of the restored teeth, the spatial reference points are necessary for reproduction, which can be divided into local and general.

We relate to local spatial guidelines we see the topography of the dentinoenamel junction, then topography of the tooth cavity surrounded by preentin, the cervix of the tooth and the outer surface of the preserved enamel.

To the general spatial guidelines, which are the rhythms of the teeth in the dental row shift, we attribute in the form of vestibular, oral and contact surfaces of the teeth in the dental row, the position of the marginal one's ridges, cusps and fissures, height ratio front teeth, especially the upper ones, multiple contact between teeth, occlusal form of dental rows (Spee's curve), functional positions of occlusion and driving ways, etc.

In the indirect restoration of teeth, when restoring these teeth are prepared for permanent prostheses, there are no such local spatial guidelines as the outer surface of intact enamel, on the working model of which is not determined by the dentinoenamel junction, and therefore laboratory modeling of teeth and bite is made in the articulator according to general rules spatial guidelines.

In the direct restoration of teeth, it is easy to detect the dentinoenamel junction, behind it and the cervix of the tooth to determine the lost external contours of the enamel and combine them with the anatomical form of the restored tooth. Very important local space is the second reference point: in all teeth, the dentin is topographically vertical and does not go beyond the cervix of the tooth!

Ago, having the cervix of the tooth as a local spatial origin guideline, you just need to rebuild the dentin strictly vertically from the cervix, then the surface is obtained will be found dentinoenamel junction, and by adding a composite to the thickness of the enamel, you will get the lost outer surface of the tooth crown.

The equator of the tooth crown is formed exclusively by enamel score!

Types of Direct Tooth Restoration Techniques

It is used to restore the anatomical shape of teeth and bite in direct restoration several techniques: Free technique, Molding technique, Shell technique, Full arc technique [1, 2].

Free hand restoration provides arbitrary restoration of the anatomical shape of the things that a dentist needs, in addition to knowledge, well-trained skills, a sense of form and appropriate talent. And this is the only technique for which teeth and bite modeling in the articulator can to be used only as a visual sample [3, 4].

Molding technique provides teeth and bite modeling in the articulator, restoration according to the patterns of oral and vestibular of tooth surfaces in each sextant separately. Having obtained the outer surfaces of the teeth from the positional cusps,

you can easily reproduce the contact and occlusal surfaces in free technique [5, 6].

Shell technique and Full arcs technique involve the manufacture of volume silicone templates on a separate one sextant and for the entire tooth row with a single moment restoration of all teeth [5, 7].

All of the listed techniques, except for Free hand technique, require adhesive procedures on several teeth or on all teeth at the same time, which calls into question the issue of achieving high-quality adhesion of restorative materials to dental tissues.

A Clinical Example of Change the Composite Restorations

A 48-year-old patient applied for a consultation with total composite restoration of all teeth and bite, which was carried out 8 years ago with cause of tooth wear. A good result of restoration in the absence of complaints about functional disorders, and each dentist has the right to his own author's features in the form of restored teeth, the main thing is that the occlusion is functional.

When there is a request from patients to replace restorations from good to better, a dentist should always expect that he can become just the next in turns. Therefore, the anatomical shape of the restored teeth and bite should be carefully analyzed!

Appearance of Teeth Restored with Composite at The Time of Application

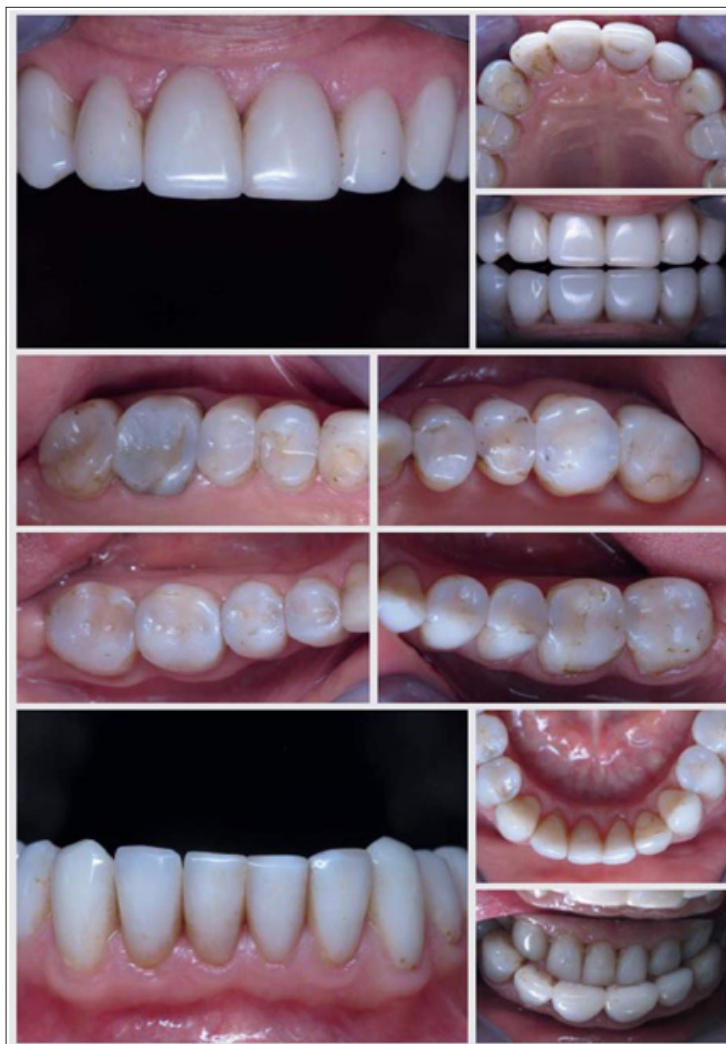

Figure 1

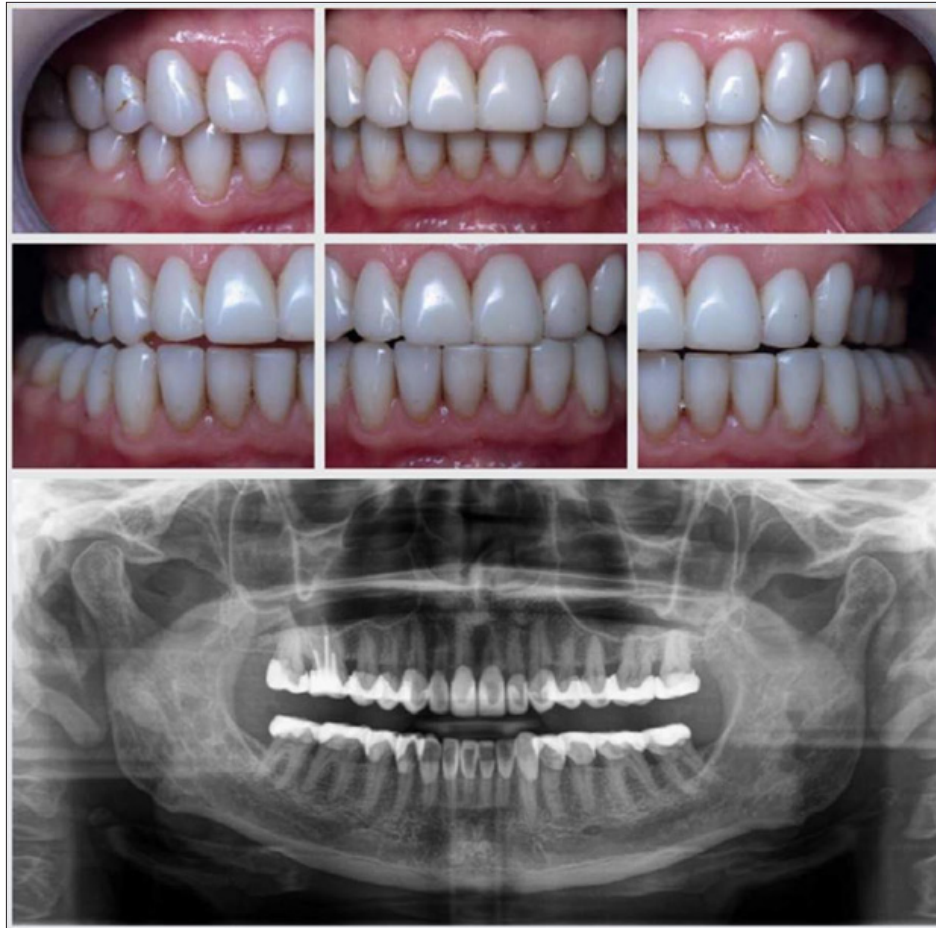

Figure 2

In the anatomical form of the upper and lower front teeth, you can pay attention to the thickness of the cutting edges of the incisors, which are too thick (the standard thickness of the cutting edges should be 1.3 mm in within 1 mm from the edge and determined by a caliper). With such cutting edges, it is convenient to chew, but it is difficult to bite off, which is the main thing the function of these functionally active teeth.

Thickened restored teeth, as a rule, are as a result of the implementation of the patient's request to change the color of the teeth from normal to "theatrical", and the artificial color of the teeth is then achieved by total covering of teeth with veneers.

It is clearly visible that the anatomical shape of the posterior teeth has significant disadvantages: a flat chewing surface with a visually sufficient height of the crowns, the ridges of the cusps, which should ensure chewing. This shape of the chewing surface can also be the result of the wear of restorations in the absence of the use of protective mouthguards.

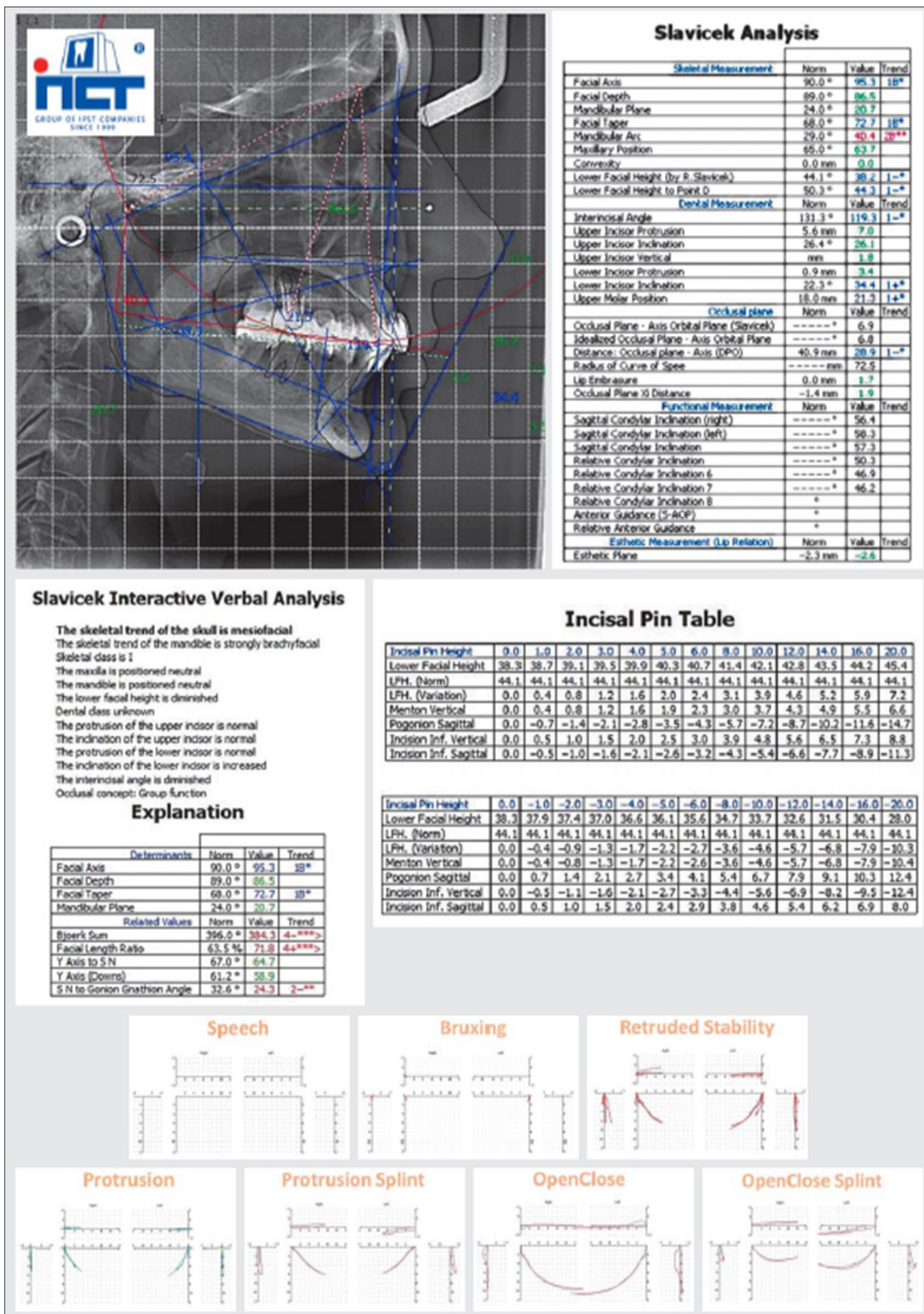
The bite shows an asymmetric ratio of the teeth: fissure-cusps ratio of the teeth on the right and cusps ratio of the teeth on the left with a shift of the artificial middle line of the lower dentition to the left.

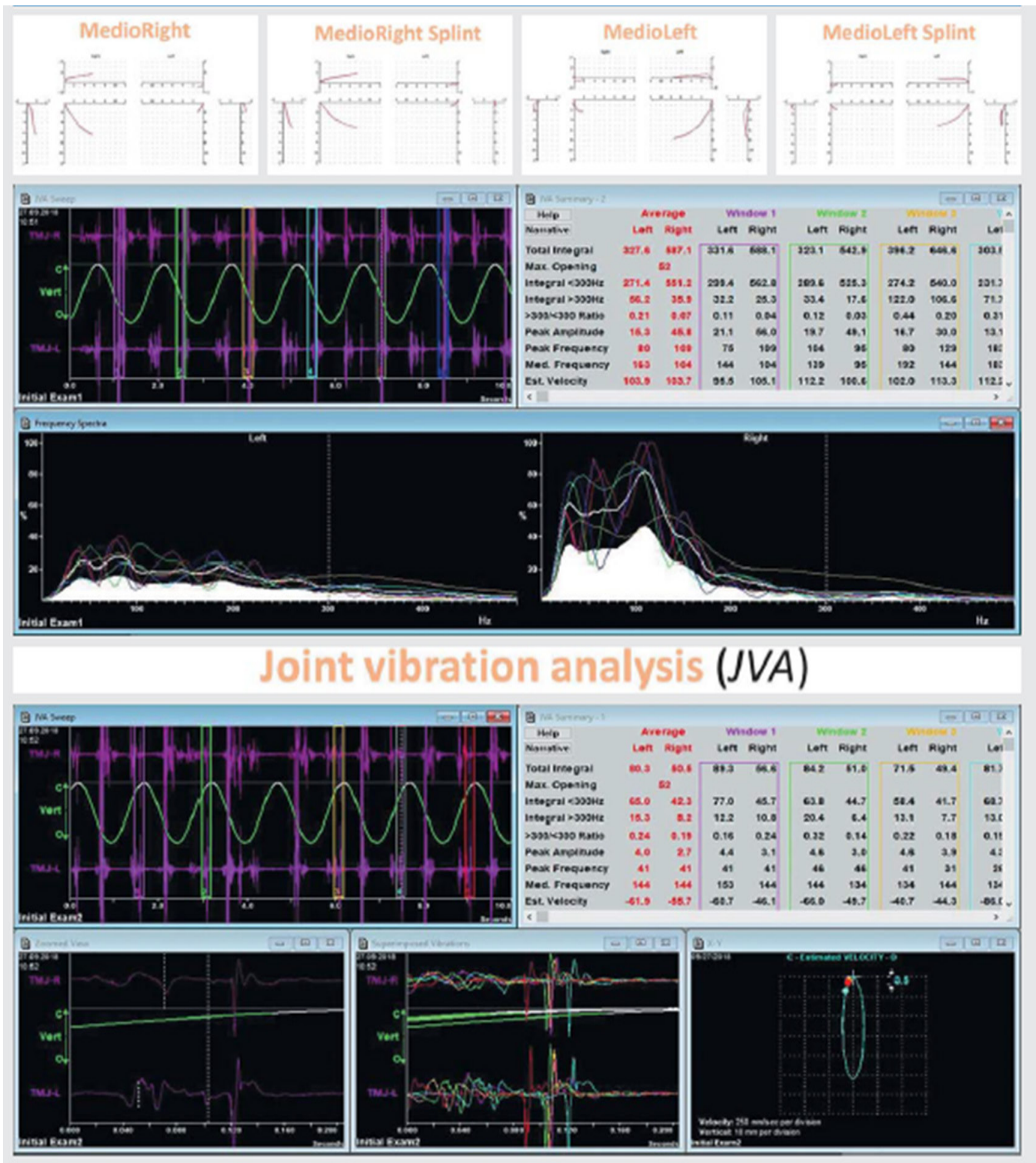
Functional bite positions are demonstrated correct ratio of teeth, and panoramic X-ray - lots and lots of composite...

Bite Diagnostics According to Slavicek

The artificial surface of the teeth made of composite is a very unreliable guide for finding the lost shape of the teeth! Therefore, in the absence of natural guidelines to achieve the correct anatomical shape of the teeth, it is worth sending the patient to another clinic for a functional examination in the hope that she will remain there for prosthetics.

Figures 3 and 4



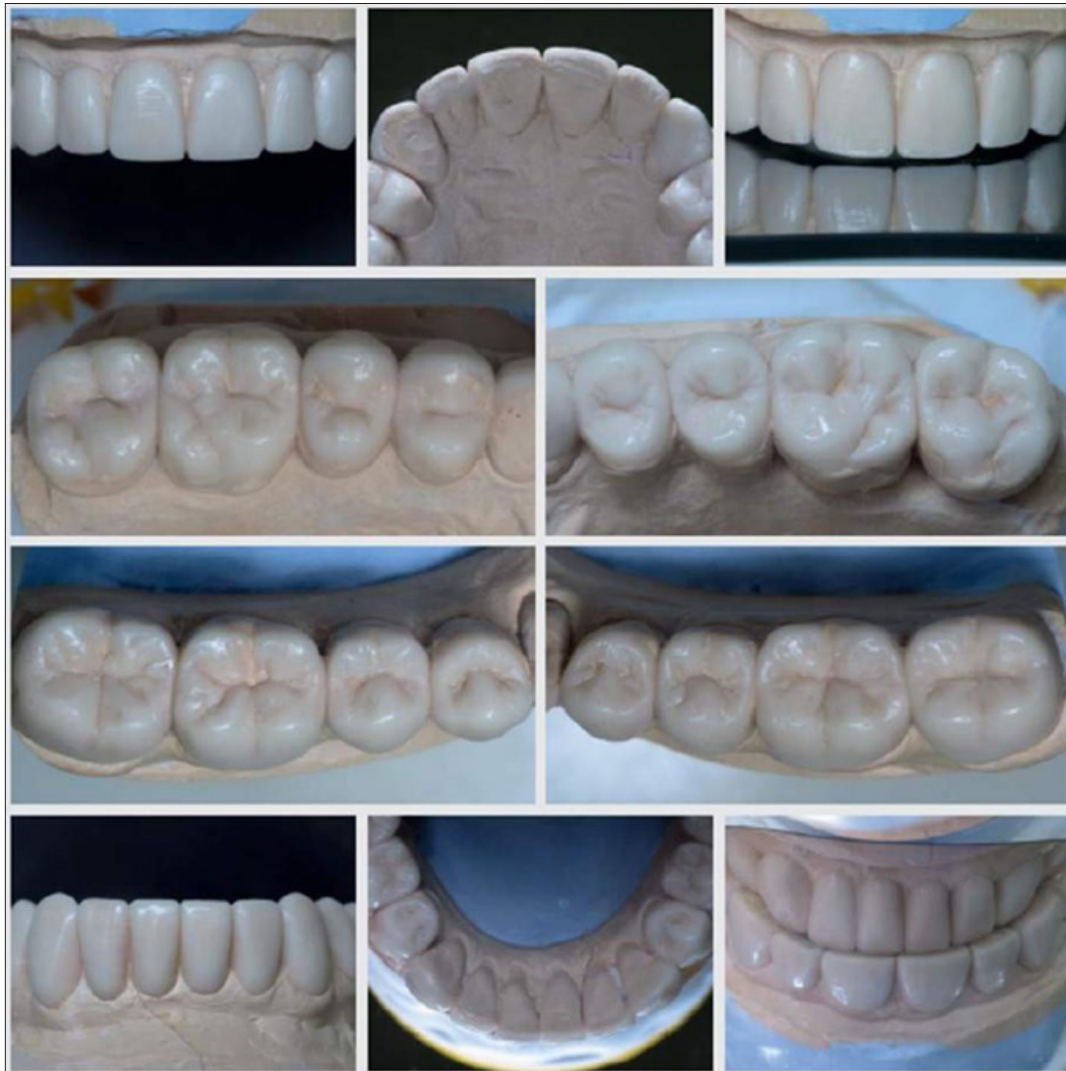

The conclusions of the examination according to Slavicek are disappointing by doctor Svitlana Fedorenko, IPST clinic (Kyiv, Ukraine) [8]:

- Chronic generalized periodontitis II degree of severity, stage of exacerbation.
- Multiple recessions in the area of teeth 17, 16, 27, 26, 11, 21, 31, 37, 41, 42, 43, 46, 47.
- Secondary caries in the area of teeth 17, 16, 15, 14, 11, 21, 23, 25, 26, 27, 36, 46.
- Pathological wear of teeth.
- Skeletal class I with a tendency to class II due to retroposition of the lower jaw. Reduction of vertical dimensions of occlusion.
- Musculoskeletal dysfunction”.

It should be remembered that the initial examination always aims to show a worse condition of the teeth and bite than it may actually be.

Figures 5: Wax modeling of teeth



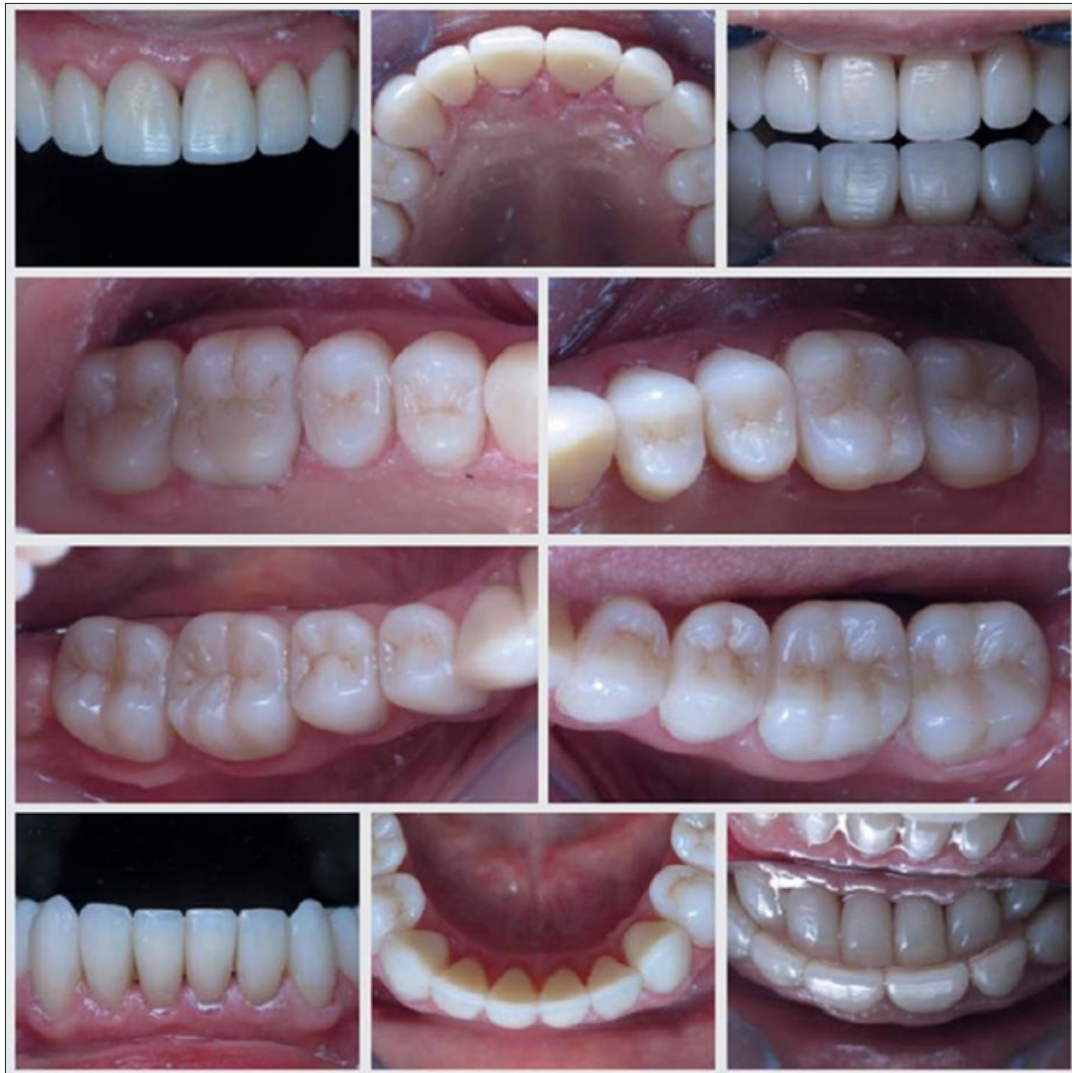It will be possible to conduct wax modeling of teeth and bite is the next step in the hope that this systematic restoration of teeth and bite based on individual natural guidelines will bypass us...

We received the result of wax modeling of the teeth and bite in the articulator according to Slavicek (usually the clinic where the wax modeling was done cannot borrow the same articulator, and have to be satisfied with only individual models without the possibility of verification functional positions of occlusion) [8]. For equipment many natural guidelines are missing: not visible the crown of the teeth, not additionally dentinoenamel junction. Therefore, the configured articulator - the only opportunity to find the original shape of the teeth through the bite and temporomandibular joints!

Wax modeling is done professionally (technician Volodymyr Antipchuk, IPST clinic, Kyiv, Ukraine): cutting edges and the presence of incisors within the anatomical norm (with preservation of the shift of the lower central line to the left), the chewing surfaces of the posterior teeth look flawless (the pronounced *Crista Obliqua* on the upper first molars, which in combination with the distal buccal cusp of the lower first molars should resist of distalization of the lower jaw).

However, the upper central incisors do not reach the area of the occlusal dental mirror attached to the upper premolars...

Figures 6: Composite Modeling of Teeth



A series of photos, identical to the wax-up photos, shows the immediate results of a direct tooth restoration, performed along spatial guidelines, such as the tooth cervix and dentinoenamel junction, exposed after removal of previous restorations. Thanks to open spatial guidelines, these restorations made in free technique without using templates!

Composite restorations have been replaced during two restoration sessions as usual algorithm [9, 10].

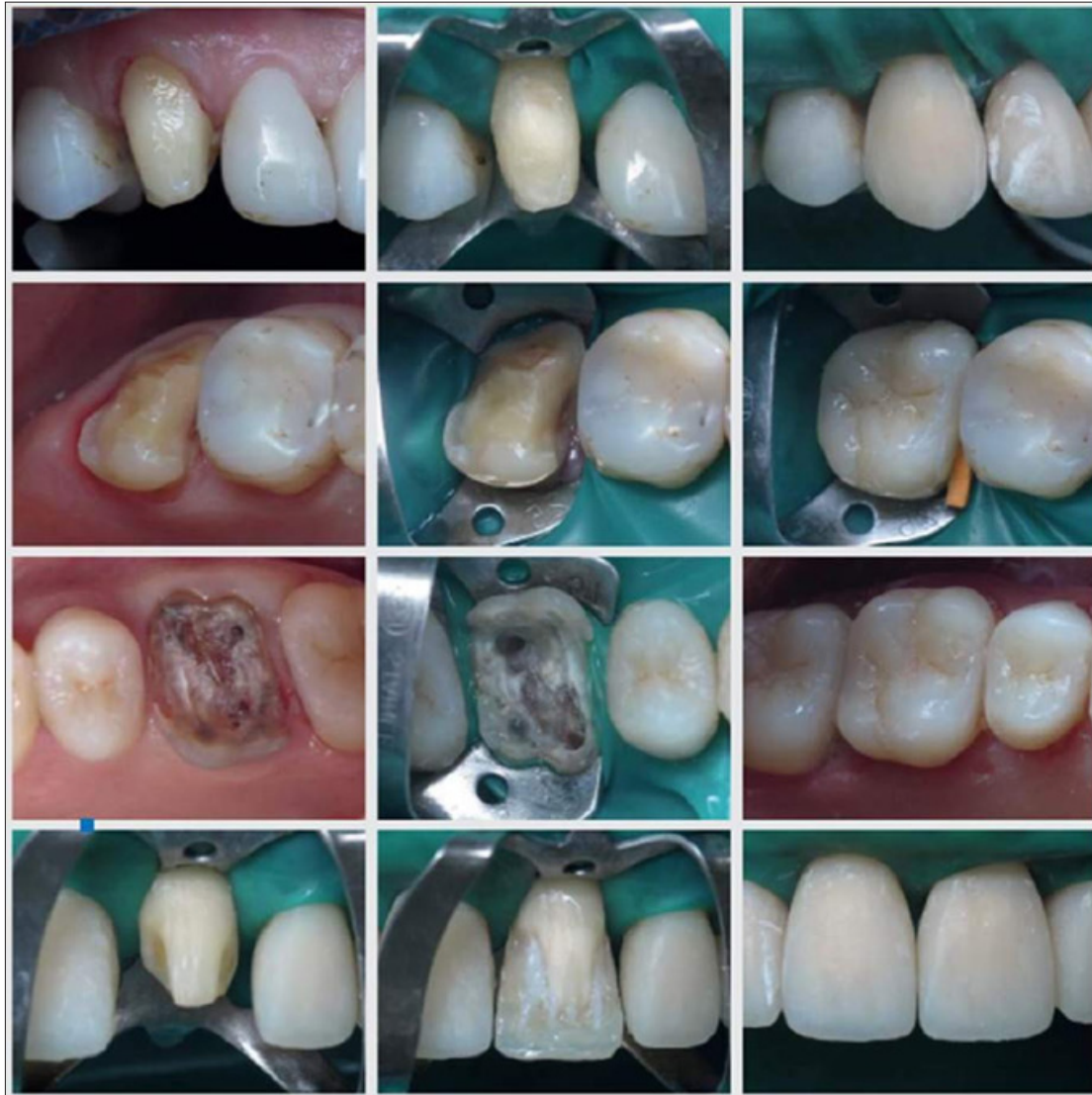During the first restoration session, restorations were replaced on all upper teeth in the following sequence: canines, posterior teeth on the right and left, incisors.

Control over occlusion consisted in checking the symmetry of canines and premolars with the assistance of an occlusal dental mirror, maximum contacts of the upper molars with the lower ones, which served as a bite template, and compliance with the ratio along the central line.

The restorations on all lower teeth replaced during the second restoration session in the following sequence: posterior teeth on the right and left, canines and incisors.

Control over occlusion consisted in maintaining the relationship along the central line, maximum contacts of the supporting cusps and the absence of contacts on the guiding cusps and on the outer surface of the supporting cusps with frequent closing of the teeth in the central relationship.

Figures 7: Replacement of Restorations in The Upper Teeth



Examples of the use of spatial guidelines when replacing restorations in upper teeth.

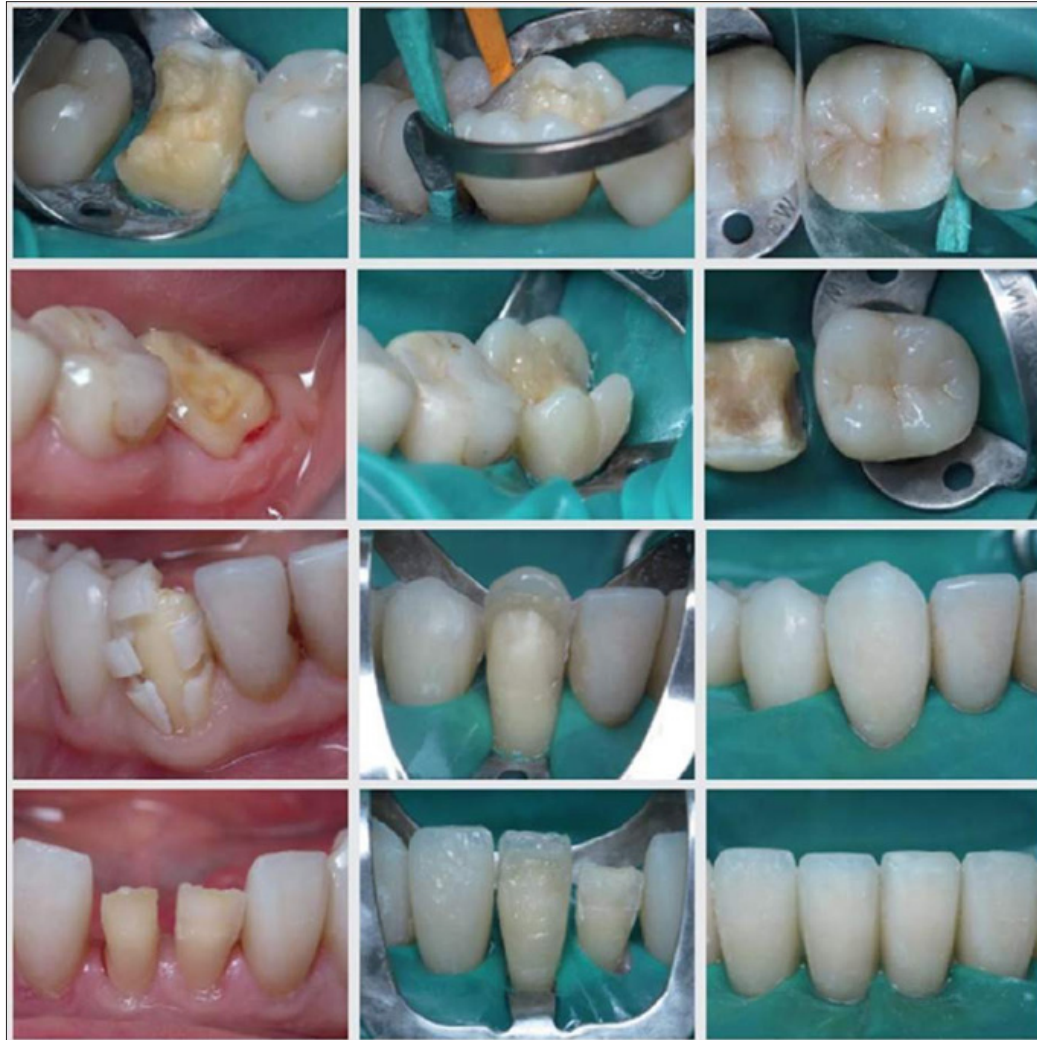The upper canines are restored in the first step according to our algorithm. After removal of the composite of the previous restoration in tooth 13, only the cervix of the tooth can be completely “readable”. Artificial dentin was built vertically from the cervix, and in this way the missing dentinoenamel junction was found.

In tooth 17, the cervix of the tooth and the oral surface of the external enamel were used as spatial guidelines. The vestibular surface is reconstructed from the cervix tooth, focusing on the contour of the vestibular surface of the first molar.

For reconstruction of tooth 16 after endodontic retreatment the cervical contour of the tooth and the contours of the oral and vestibular surfaces of the neighboring teeth are used as spatial reference points. It can be seen that the premolars were previously rebuilt. From the conclusion construction of the entire tooth row sextant the closure of all right upper teeth with lower teeth was checked.

Restoration of tooth 21 was final in the first restoration session, when the spatial guidelines of not only the dental tissues of the tooth itself, but also the entire tooth row are already determined. To achieve the color of the restored tooth, the contours of the pre-dentin, lost due to caries damage to the contact surfaces and subsequent restorations, were reproduced with a bright opaque shade of the composite.

Figures 8: Replacement of Restorations in The Lower Teeth



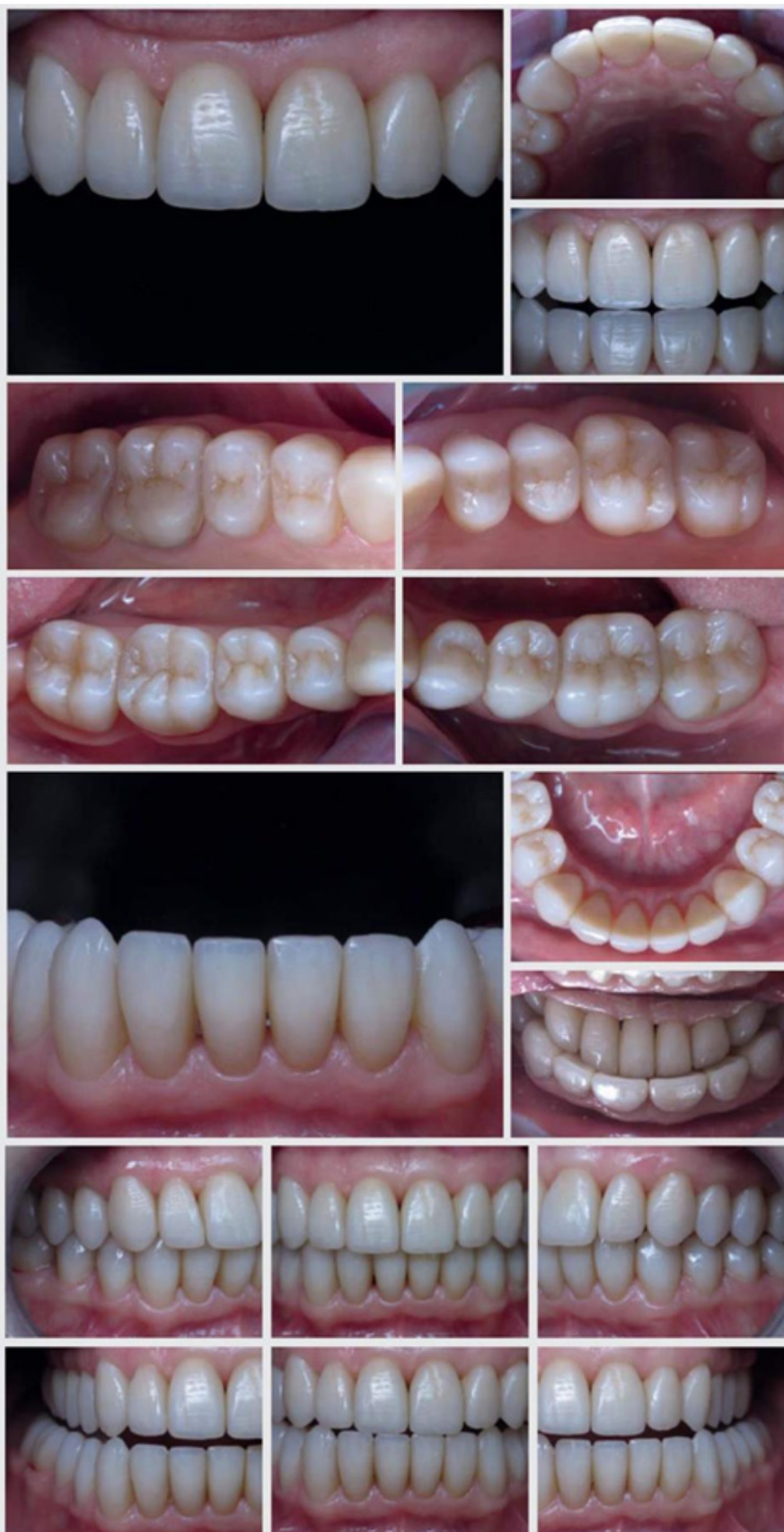Examples of the use of spatial guidelines when replacing restorations in lower teeth. The cervical contour of the tooth, the oral surface of the outer enamel together with the preserved height were used as guidelines during the reconstruction of the crown of tooth 46 oral cusps, as well as the contour of the vestibular crown surfaces of adjacent teeth. When constructing the contact surfaces, asymmetry was ensured by vertically installed wedges of different sizes (the contact point should be located vestibular).

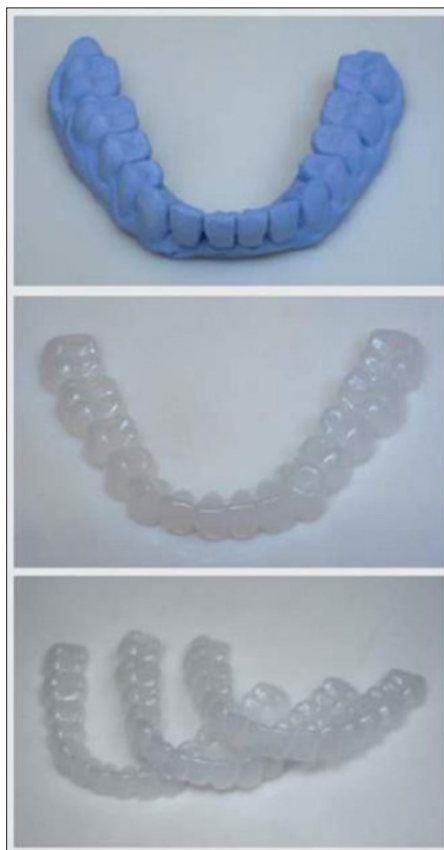After removing the previous restoration in tooth 37 had to focus only on the tooth cervix and the rhythm of the teeth in the sextant. After construction restoration to the Class I defect stage was removed rubber dam, and after a 45-minute break (to eliminate distalization of the lower jaw due to prolonged sitting in a chair), the cusps were checked in occlusion, and the occlusal surface was completed after re- isolation.

The reconstruction of tooth 43 demonstrates the presence of continuous debonding, and this is not only a good reason for replacing previous restorations, but also a reduction in damage to the natural tooth tissues, because in this tooth, superficial mechanical preparation is sufficient.

In the final reconstruction of the central incisors the reference points were the cervixes of the teeth and the calculated mesio-distal dimensions of the crowns, observed with a caliper.

Figures 9 and 10: Appearance of Teeth Restored with Composite, One Month after Replacement of Restorations

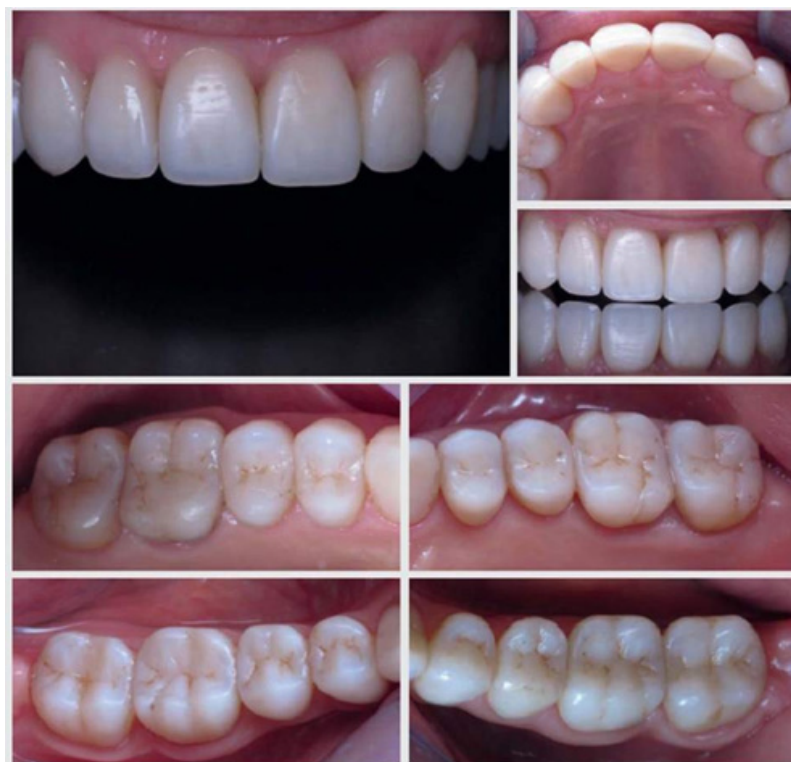


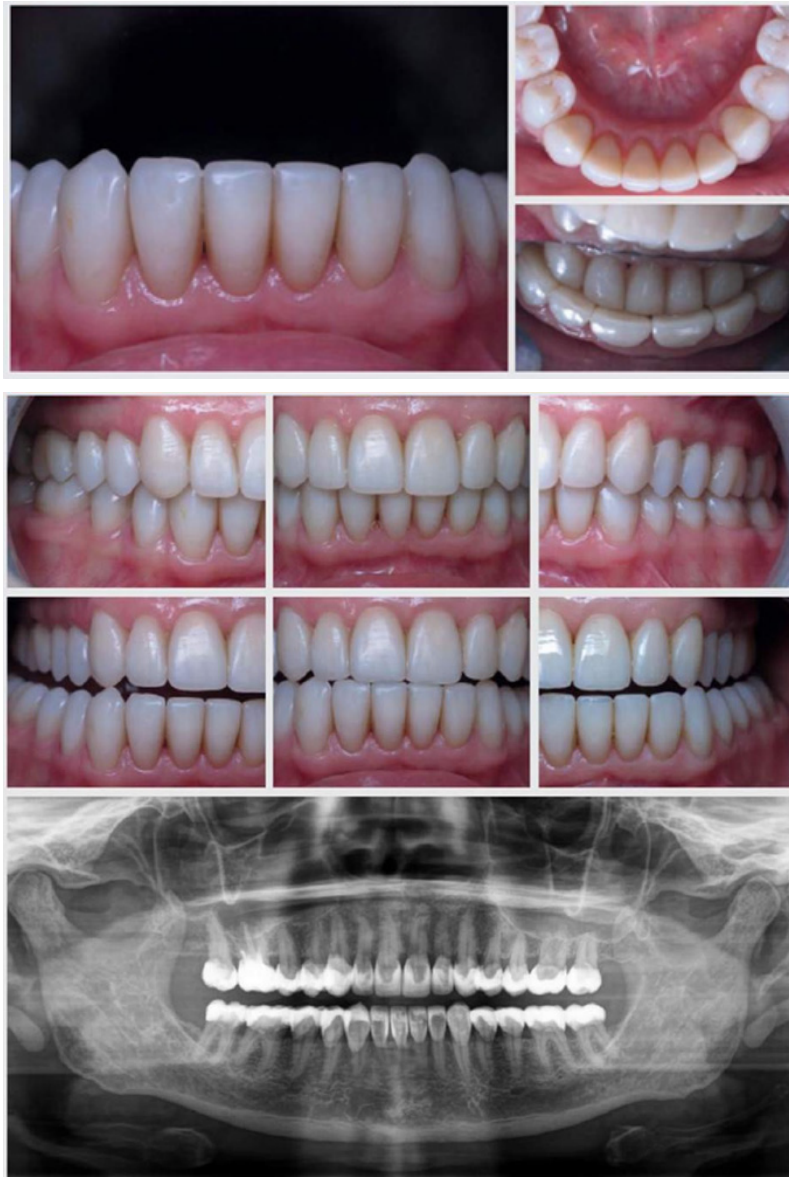
Figures 11

Immediately after the restoration, patients are obliged use caps that isolate the upper and lower teeth between each other during the clenching of the teeth as a result reaction to stress. We usually make it first three caps: night guard, day guard and spare, but, if necessary, their number can be increased.

Figures 12 and 13: Appearance of Teeth Restored with Composite, Three Years after Replacement of Restorations





Three years is the term for the end of our clinic's guarantee, two of which are covered by medical risk insurance. Clinically a three-year term demonstrates the first results of using by the patient of restored teeth and bite, the dynamics of wear of occlusal surfaces, which depends on the severity of parafunctions, the level of stress and accuracy in using protective mouthguards.

Condition of restored teeth and bite visually a satisfactory, shiny surface of the composite indicates the correct use of hygienic toothpastes with correct RDA- index that clean and polish.

There are no chips and delamination of the composite.
The condition of the gingival margin around the restored teeth is satisfactory.

The occlusal surfaces of the lateral teeth are slightly different worn on the left through cusps contacts average the line in the central ratio is shifted to the left, but the canine ratios are symmetrical.

The functionally active occlusal positions are normal and show separate contacts of the upper central incisors and canines.

On the panoramic X-ray, as well as on the systemic one replacement restorations, a lot of x-ray contrast composite, the periapical tissues of nonvital tooth 16 are unchanged, there are no steps in the fit of the composite along the cervix on the contact surfaces of the teeth.

The first long-term results of the condition of the teeth and bite prove that the systematic replacement of restorations with debonding in a free technique three years ago was quite successful, and spatial guidelines helped to achieve this [11, 12].

Conclusion

The presented clinical case demonstrates how lack of common spatial guidelines or in the absence of confidence in them, teeth can be restored in an anatomical form close to the one lost due to pathology and dental interventions, using local spatial guidelines.

As local spatial guidelines, used the cervix of the tooth and the dentinoenamel junction, because in each tooth, the dentin does not emerge topographically beyond the cervix, going vertically from it, and the convex equator of the tooth crown is formed only due to the thickness of the enamel. This can be easily verified by analyzing of any radiographs with intact teeth.

It is interesting that in the case when the patient has flat contact surfaces of the front teeth and small spaces between them, then on the X-ray Figure it is possible to see too thin enamel with a normal shape dentin - vertically from the neck.

Closure of such spaces should not be achieved by shifting the teeth through orthodontic intervention, but it is necessary to simply complete the enamel with a composite to the thickness that is absent, and this will give a stable predicted result, which can also be achieved thanks to the use of local spatial guidelines.

In this clinical case, Slavicek wax modeling gave an example of tooth shape and occlusion based on temporomandibular joints and mandibular movements, but we achieved the same result based on local spatial guidelines. Re-diagnosis of the bite state according to Slavicek confirmed the correctness of the anatomical shape of the teeth, found by an alternative method. Because the correct anatomical shape of the teeth ensured correct bite and normalization of functions.

When modeling teeth in Slavicek's system special attention is paid to the relationship of the first molars, where the distal buccal cusp of the lower first molar when closing the teeth is covered behind by the anatomical formation of the Crista Obliqua of the upper first molar, and this block resists the distalization of the lower jaw. This ratio should be achieved when restoring teeth in any technique, but it will work to its full extent only when restoring the primary anatomical shape of all teeth and bite. The Slavicek system is necessary for all dentists, which restore teeth!

The service life of restorations in restored teeth and a restored bite should be at least 10 years, but it depends not so much on the strength and wear resistance of composite materials, but on the severity of parafunctions and the level stress, as well as from diligence in using a protective cap both at night and during the day. Renovation of the restored teeth without full replacement of the restorations should be done when the wear of the supporting cusps from the composite will lead to the restoration of the functional overload of the anterior teeth and if this is done only after 10 years, then this clinical case can be considered completely successful [4,5].

The author expresses his gratitude to the dentist Svitlana Fedorenko and the dental technician Volodymyr Antipchuk from the dental clinic IPST, Kyiv, for understanding and cooperation in this matter clinical case.

References

1. Dietschi D, Argente A (2011) A Comprehensive and conservative approach for the restoration of abrasion and erosion. Part I: concepts and clinical rationale for early

intervention using adhesive techniques. *Eur J Esthet Dent* 6: 20-33.

2. Dietschi D, Argente A (2011) Comprehensive and conservative approach for the restoration of abrasion and erosion. Part II: Clinical procedures and case report. *Eur J Esthet Dent* 6: 142-159.
3. Dietschi D (2022) State-of-the-Art Patient-Centered Treatment & Management of Tooth Wear. *J Cosmetic Dent* 38: 30-43.
4. Spreafico R (2010) Composite resin rehabilitation of eroded dentition in a bulimic patient: a case report. *Eur J Esth Dent* 5: 28-48.
5. Ammannato R, Ferraris F, Marchetti G (2015) The "index technique" in worn dentition: a new and conservative approach. *Int J Esthet Dent* 10: 68-99.
6. Dietschi D, Saratti CM (2020) Interceptive treatment of teeth wear: a revised protocol for the full molding technique. *Int J Esthet Dent* 15: 264-286.
7. Ramseyer ST, Helbling C, Lussi A (2015) Posterior Vertical Bite Reconstructions of Erosively Worn Dentitions and the "Stamp Technique" - A Case Series with a Mean Observation Time of 40 Months. *J Adhes Dent* 17: 283-289.
8. Slavicek Rudolph (2008) Chewing organ. Functions and disfunctions. *M: Azbuka* 283-305, 354-424.
9. Radlinsky S (2007) System restoration of all teeth with increased abrasion. *DentArt* 3: 38-48.
10. Radlinsky S (2018) Synchronomyography in the systemic recovery novel occlusion. *DentArt* 2: 35-54.
11. Radlinsky S (2019) System renovation of the restored teeth: upper teeth. *DentArt* 2: 15-28.
12. Radlinsky S (2019) System renovation of the restored teeth: lower teeth. *DentArt* 3: 25-34.

Copyright: ©2023 Serhiy Radlinsky. This is an open-access article distributed under the terms of the Creative Commons Attribution License, which permits unrestricted use, distribution, and reproduction in any medium, provided the original author and source are credited.