

Case Report
Open Access

Effective Management of Dens in Dente: A Case Report

Amina Laabidi^{1,2}, Yamina Elelmi^{1,2*}, Chayma Ben Arbia^{1,2}, Selsebil Laajimi^{1,2}, Fatma Masmoudi^{1,2}, and Ahlem Baaziz¹

¹Pediatric and Preventive Dentistry Department, Faculty of Dental Medicine of Monastir, Tunisia

²Laboratory of Biological Clinical and Dento-Facial Approach (ABCDF Laboratory LR12ES10), University of Monastir, Monastir, Tunisia

ABSTRACT

Dens Invaginatus (DI) is caused by the enamel organ invagination of the tooth papilla during odontogenesis.

When viewed radiographically, DI typically appears as a radiolucent invagination that is either restricted to the dental crown or extends into the root and is encircled by radiopaque enamel. The invagination can hold onto saliva, food particles, and bacteria since it is exposed to the mouth cavity. Bacterial cells and products can infiltrate from the invagination through the dentin tubules to reach the pulp and can eventually cause infectious complications.

Because of the anatomic intricacy of dens invaginatus, endodontic care of these teeth can be challenging. The endodontic implications of this aberration are discussed in this study, along with the current treatment recommendations that take into account anatomical, pathological, and technological factors.

This article aimed to clarify the diagnostic steps and treatment options and to provide dental practitioners with valuable insights and recommendations when handling similar cases in their clinical settings.

***Corresponding author**

Yamina Elelmi, Pediatric and Preventive Dentistry Department, Faculty of Dental Medicine of Monastir, Tunisia.

Received: May 24, 2025; **Accepted:** June 03, 2025; **Published:** June 27, 2025

Keywords: Cone-Beam Computed Tomography, Dens in Dente, Root Canal Therapy, Incisor, Apexification

Introduction

"Dens in dente," also referred to as dens invaginatus, is an inherent dental irregularity characterized by the formation of a deep infolding or invagination within the crown or root of a tooth during its developmental stage. Its prevalence is between 0.3% and 10% [1].

Although its etiology is controversial and several theories try to explain its formation: it is widely accepted that dens invaginatus may result from an invagination of the enamel organ into the dental papilla during odontogenesis, before calcification occurs [2].

It has several clinical manifestations, many attempts to categorize them, the most widely used classification system was produced by Oehler (Figure1) and this system separates these lesions into three simple categories [3].

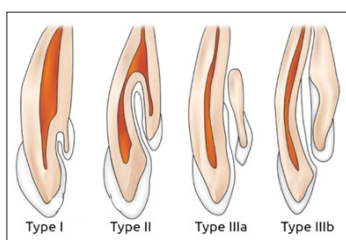


Figure 1: The Different Types of Dens Invaginatus (Oehlers' Classification)

Class I: This is a partial invagination that is confined to the crown of the tooth. These lesions involve dentine and enamel but do not extend past the cement-enamel junction (CEJ) or involve the pulp.

Class II: This partial invagination extends beyond the crown of the tooth and into the root, beyond the cement-enamel junction. These lesions may or may not involve pulp, but remain within the anatomy of the root. There is no communication with the periodontal ligament.

Class III:

Class III a: This complete invagination extends through the root. It communicates with the periodontal ligament through a second foramen on the lateral aspect of the tooth. There is usually no involvement of the pulp itself, but it causes a significant anatomical malformation.

Class III b: This complete invagination extends through the root, and communicates with the periodontal ligament at the apical foramen. Again, often there is no direct involvement of the pulpal anatomy but the lesion causes significant disruption to the dental anatomy.

Diagnosis

This tooth abnormality is often asymptomatic and the crowns of affected teeth may show very little external deformity [4,5].

Radiographic examination is essential to a correct diagnosis of dens invaginatus. The invagination usually appears as a radiolucent pocket lined by radiopaque borders (enamel) and is either confined to the crown or extended into the root. Communication between the invagination and the apical or lateral periodontal ligament may be evident and associated with a periapical or lateral bone

radiolucency. Its detection is typically not systematic; rather, it is usually identified incidentally through radiographic examinations or as a result of complications affecting the affected tooth [4].

The aim of this case report was to offer insightful information about the diagnosis and management of patients with dens in dent

Observation

A 9-year-old female (B.G) patient consulted the Pediatric and Preventive Dentistry Department in the Faculty of Dental Medicine of Monastir (Tunisia) with cellulitis associated with the maxillary lateral right incisor (12), due to a trauma that led to the tooth necrosis.

Pertinent extraoral examination was carried out showing fever, facial swelling, firm palpation and difficulty swallowing.

Intraoral clinical examination revealed that percussion of the incisor was painful. Sensitivity tests and thermal test were negative. Mobility and periodontal probing were physiological. Periapical radiographs were performed and it showed a dens invaginatus in tooth (12), as well as a radiolucent lesion.

The case was examined in detail using Cone-Beam Computed Tomography (CBCT) (Figure 2) to carry out a correct approach and confirm the presumptive diagnosis.

The final diagnosis was established as a dens invaginatus type IIIa, with pulp necrosis and symptomatic apical periodontitis.

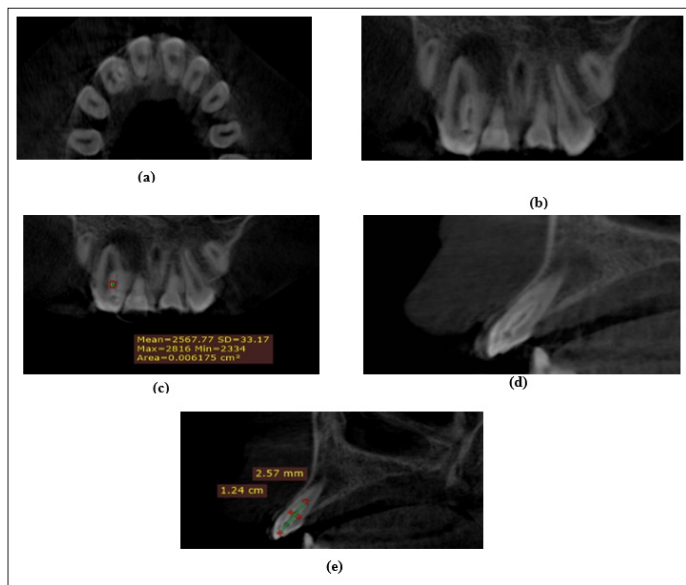


Figure 2: (a) CBCT Axial Section of the Lateral Incisor Showing the Invagination; (b, c) CBCT Coronal Section: Type IIIa Di Lesion and a Periapical Radiolucency; (d, e) CBCT Sagittal Section with the Dimensions of both the Principal Canal and the Invagination

Management Strategy

Based on the clinical and radiological findings (Figure 3a), it was decided to proceed with endodontic treatment without removing the dens invaginatus in order to conserve maximum tooth structure.

First session only the main root was treated and Viopex medication was provided (Figure 3b). Upon achieving correct access, a prek hand files size were employed to establish canal permeability. The working length was determined using an electronic apex locator and verified radiographically. After establishing an

adequate glide path, rotary instrumentation was conducted using a multi-instrument system (RevoS) up to size 25.06. Mechanical instrumentation was accompanied by regular irrigation with 5.25% sodium hypochlorite and 17% liquid EDTA.

Dual Antibiotic therapy with Augmentin and Flagyl was initiated and a CBCT was requested to help with the DI evaluation in the next session.

During the second appointment, the proper access to the invagination was achieved and it was treated by using preK hand files. Pus drainage was ensured. The working length was determined using an electronic apex locator. Then, intracanal medication (conventional calcium hydroxide) was placed.

At last, during the third consultation, both the root canal and the invagination were filled using gutta-percha cones and Endoplus root canal sealer (Figure 3c). A direct composite reconstruction was then applied to restore and rehabilitate the coronal morphology. Postoperative radiographs were taken to confirm the sealing of the canal system. Regular clinical and radiological follow-up was conducted: by day 7, there was a complete resolution of symptoms and clinical signs, and at the 6-month follow-up, a noticeable reduction in the radiological periapical lesion was observed (Figure 3d).

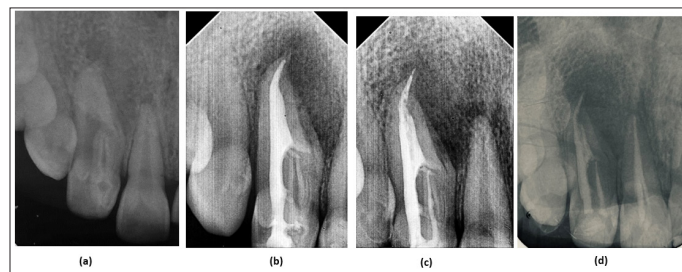


Figure 3: (a) Preoperative Radiograph; (b) Viopex Medication in the Root Canal; (c) Final Obturation of Both the Root Canal and the Invagination; (d) 6-Month Post-Op Radiograph

Discussion

The endodontic treatment success hinges on achieving thorough cleaning the root canals, their disinfection and sealing [6]. Teeth with dens invaginatus (DI) exhibit significant anatomical variations, complicating treatment success [7]. To understand internal anatomy, diagnose accurately, and tailor treatment to each patient's clinical situation, diagnostic imaging techniques were employed before treatment. Cone-beam computed tomography (CBCT) was useful due to its ability to reveal intricate anatomical details, particularly useful for diagnosing and managing teeth with unusual anatomy [7-9].

Different management strategies have been proposed based on the condition of the dental pulp and its complexity [10]. In cases of early detection of DI, a preventive approach could involve sealing the invagination to prevent potential pathology [10]. However, if there is pulp involvement or periapical pathology present, endodontic treatment becomes necessary [10].

In this case, including a Type IIIa lateral incisor, treatment was carried out in three sessions with calcium hydroxide medication in between to harness its antimicrobial and tissue-dissolving properties [11]. Identifying whether both the invagination and root canal require treatment is crucial for a conservative approach. In cases where the invagination and main canal are treated separately, preservation of dental tissue is prioritized to enhance long-term

survival and structural integrity post-endodontic treatment.

It is challenging to properly shape and clean the root canal system due to its complex and uneven volume. In order to clean the morphology of the root canal system in teeth with dens invaginatus, irrigation combined with ultrasonic root canal system cleaning has been described as an effective disinfection method. Warm gutta-percha methods, such as vertical condensation or thermoplastic filling techniques, have been suggested for the obturation of such teeth [12].

Some endodontic failure, due to anatomical issues or inability to reach all areas of the root canal system, should be treated surgically. In otherwise hopeless cases, retrograde surgery may even be suggested [13].

Only teeth with significant anatomical abnormalities that cannot be treated in any cited way, should be extracted. Extraction is also recommended in cases where the crown morphology is aberrant, causing issues with appearance or functionality [14].

Conclusion

Teeth affected by dens invaginatus lesions are more likely to developing pulpal diseases. This makes endodontic treatment particularly challenging due to the unpredictable and irregular internal anatomy of such teeth. While advancements like CBCT imaging and modern endodontic techniques have enhanced our ability to manage these anomalies, it's crucial to identify and treat these lesions early to prevent pulpal issues and the need for complex endodontic procedures. Early intervention can help avoid complications [15].

References

1. Hovland EJ, Block RM (1977) Nonrecognition and subsequent endodontic treatment of dens invaginatus. *J Endod* 3: 3.
2. Rotstein I, Llamas E, Choi KS (2019) Endodontic therapy in teeth with anatomical variations. In: Rotstein I, Ingle JJ, editors: 866-869.
3. Oehlers FA (1957) Dens Invaginatus. I. Variations of the invagination process and associated anterior crown forms. *Oral Surg Oral Med Oral Pathol* 10: 1204-1218.
4. Gallacher A, Ali R, Bhakta S (2016) Dens invaginatus: diagnosis and management strategies. *Br Dent J* 221: 383-387.
5. Khabbaz M G, Konstantaki M N, Sykaras S N (1995) Dens invaginatus in a mandibular lateral incisor. *Int Endod J* 28: 303-305.
6. Girsch W J, McClammy T V (2002) Microscopic removal of dens invaginatus. *J Endod* 28: 336-339.
7. Pradhan B, Gao Y, He L, Li J (2019) Non-surgical removal of dens Invaginatus in maxillary lateral incisor using CBCT: two-year follow-up case report. *Open Med (Wars)* 14: 767-771.
8. Agrawal PK, Wankhade J, Warhadpande M (2016) A rare case of type III dens Invaginatus in a mandibular second premolar and its nonsurgical endodontic management by using cone-beam computed tomography: a case report. *J Endod* 42: 669-672.
9. Patel S (2010) The use of cone beam computed tomography in the conservative management of dens invaginatus: a case report. *Int Endod J* 43: 707-713.
10. Teixidó M, Abella F, Duran-Sindreu F, Moscoso S, Roig M (2014) The use of cone-beam computed tomography in the preservation of pulp vitality in a maxillary canine with type 3 dens invaginatus and an associated periradicular lesion. *J*

Endod 40: 1501-1514

11. Bishop K, Alani A (2008) Dens invaginatus. Part 2: clinical, radiographic features and management options. *Int Endod J* 41: 1137-1154.
12. Best S, Ammons CL, Karunanayake GA, Saemundsson SR, Tawil PZ (2021) Outcome assessment of teeth with necrotic pulps and apical periodontitis treated with long-term calcium hydroxide. *J Endod* 47: 11-18.
13. Hülsmann M (1997) Dens invaginatus: aetiology, classification, prevalence, diagnosis, and treatment considerations. *Int Endod J* 30: 79-90.
14. Olmez S, Uzamis M, Er N (1995) Dens invaginatus of a mandibular central incisor: surgical endodontic treatment. *Journal of Clinical Pediatric Dentistry* 20: 53-56.
15. Rotstein I, Stabholz A, Heling I, Friedman S (1987) Clinical considerations in the treatment of dens invaginatus. *Endodontics and Dental Traumatology* 3: 249-254.

Copyright: ©2025 Yamina Elelmi, et al. This is an open-access article distributed under the terms of the Creative Commons Attribution License, which permits unrestricted use, distribution, and reproduction in any medium, provided the original author and source are credited.