

## Case Report

## Open Access

# Deep Dermatophytosis

Mehdi Khallayoune<sup>1\*</sup>, Asmae Abdelmouttalib<sup>1</sup>, Siham Belmourida<sup>1</sup>, Mariame Meziane<sup>1</sup>, Kassang M. Konzi<sup>2</sup>, Sarra Aoufi<sup>2</sup>, Mohamed Lyagoubi<sup>2</sup> and Karima Senouci<sup>1</sup>

<sup>1</sup>Department of Dermatology, Ibn Sina University Hospital, Mohammed V University, Rabat-Morocco

<sup>2</sup>Department of Parasitology, Ibn Sina University Hospital, Mohammed V University, Rabat, Morocco

### ABSTRACT

Deep dermatophytosis is a rare fungal infection described for the first time by Hadida and Schousboe. It is a chronic dermatophytic infection of the skin and viscera, mainly described in the Maghreb where it has an autosomal recessive transmission. Immunological studies have revealed a deficiency of cellular immunity leading to dermatophytes tolerance. Commonly, first lesions begin in childhood. Both superficial and deep dermatophytic lesions are possible. A 17 years old male patient with a history of chronic generalized pruritic erythematous-squamous lesions presented for subcutaneous abscesses of scalp and trunk. He underwent multiple antibiotic courses and surgical excisions with persistent relapses. *Trichophyton rubrum* was identified in skin biopsy and all samples sites. It was found no immunodeficiency within the limits of the blood tests conducted. Search for CARD9 protein deficiency was positive. Treatment based on Terbinafine and surgical drainage with mid improvement.

### \*Corresponding author

Khallaayoune M, Department of Dermatology, Ibn Sina University Hospital, Mohammed V University, Rabat B.P 6527 Morocco. Tel: (212)661509831: Email: khallaayounemehdi@gmail.com

**Received:** March 03, 2021; **Accepted:** March 10, 2021; **Published:** March 18, 2021

**Keywords:** Deep Dermatophytosis, Mycology, Dermatology, Genetics, Card9 Protein Deficiency

discharging pus. Toe nails and finger nails were normal. General status was conserved and no lymphadenopathy was noted.

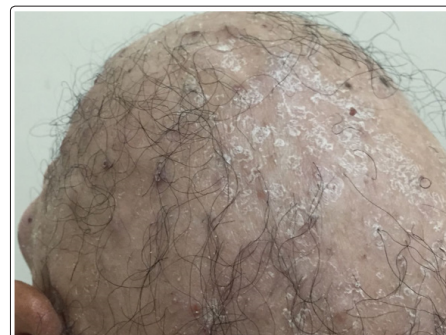### Introduction

Deep dermatophytosis is a chronic fungal infection caused by dermatophytes affecting skin, deep soft tissue and viscera. It is a rare condition mainly described in Maghreb within the same family members suggesting an autosomal recessive transmission. Recently, immunological studies have provided better understanding showing the importance of an inherited cellular immunity deficiency. The treatment is challenging with a poor clinical response to main antifungal agents. We report hereby the case of a young patient with deep dermatophytosis presenting as multiple cutaneous abscesses.

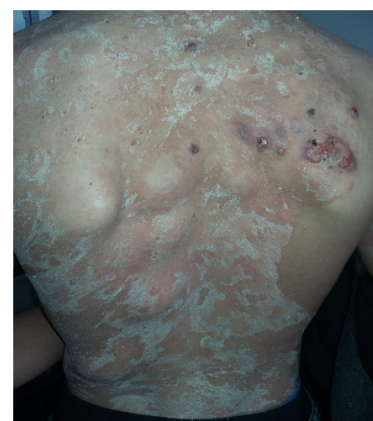### Case report

A 17-year-old young man presented with generalized itchy erythematous scaly plaques, alopecia and multiple subcutaneous nodules and abscesses. Anamnesis did not found any diabetes, unprotected sex intercourse or drug abuse. There was no consanguinity and no similar case in the family. The history began at the age of 6 with remitting and relapsing superficial fungal infections of scalp and skin leading to total loss of scalp hair. He had been treated with several oral and topical antibiotics and antifungals with poor results. At the age of nine he started presenting nodules and abscesses on trunk and abdomen that failed to heal after surgical excisions and several antibiotics courses. At the age of 16 other purulent nodules appeared on the scalp and back.

Physical examination revealed well-demarcated annular erythematous scaly plaques with 2-4 cm multiple nodules on scalp (Figure 1) and trunk (Figure 2). Some nodules were ulcerated with



**Figure 1:** Patient scalp with severe alopecia and squamous lesions



**Figure 2:** Erythematous scaly plaques and purulent nodules on the trunk

Examination of a skin biopsy specimen revealed hyperkeratosis, orthokeratosis and a polymorphous inflammatory infiltrate in the dermis with giant cells and PAS-positive fungal hyphae (Figure 3). Direct microscopic examination of all samples including skin biopsy, scales and pus showed hyaline hyphae while cultures on dextrose agar identified *T. rubrum* (Figure 4). Immunity assessment including blood count, HIV serology, and immunoglobulin quantitation was normal. Full body tomography found no internal localization of abscesses. Search for CARD9 deficiency was positive.

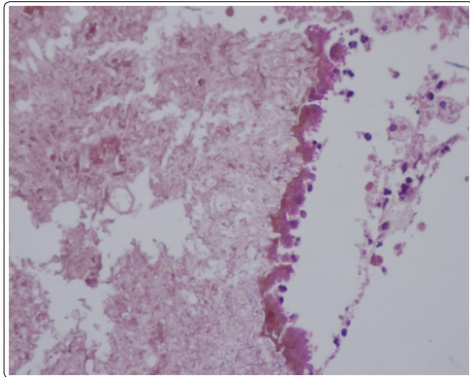


Figure 3: PAS positive staining of hyphae on skin biopsy

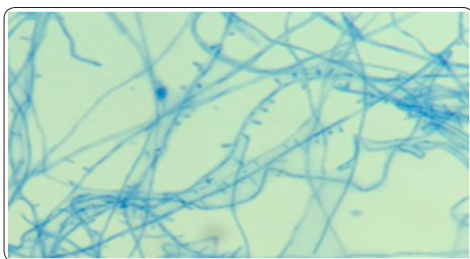


Figure 4: Pyriform microconidia after subculture on potato dextrose agar, Cotton blue Lactophenol Mount x40

Based on these findings a diagnosis of deep dermatophytosis was retained. A treatment with terbinafine 250mg/day was started allowing only slight improvement after 2 months. Higher terbinafine doses (500mg/j) were implemented with significant results after 3 months. Superficial lesions decreased and there was no more pus discharge. However, nodules remained filled by some granulations tissue and could not be removed all surgically owing to their great number. The patient is still undergoing therapy, and close follow-ups is planned.

### Discussion

The first case of deep dermatophytosis might have been reported by Sequeira in 1912[1]. In 1959, Hadida and Shousboe described other cases and studied the clinical features of what they called « dermatophytic disease » [2]. The first case in Morocco was described by Rollier in 1964[1]. Deep dermatophytosis presents as an infection of the dermis, subcutis and the internal viscera caused by a dermatophyte. This rare entity is more often described in Maghreb but may be seen in other regions [3]. As observed with our patient, first symptoms generally occur during childhood [3; 4]. Lesions often begin as recurring scalp ringworms (51, 7 %), tinea corporis (41, 4 %) or onychomycosis (6, 8 %) [3].

Skin lesions may display various aspect. Erythematous pruritic scaly plaques are the most common [3; 5-7]. As our patient, along with the progression of the disease, subcutaneous nodules of various sizes resembling cutaneous tuberculosis may also appear

[3]. Alopecia is often present and may progress to total hair loss [1]. In severe cases, the disease manifest as a life-threatening condition and extends to viscera [5; 8-10].

Histopathology of a skin biopsy shows an inflammatory granuloma of the dermis associated with acanthosis and hyperkeratosis. It also reveals PAS positive fungal hyphae as in our case [11]. Direct mycological examination of superficial and deep samples shows hyaline hypha. Cultures provide identification of the dermatophyte species. Most dermatophytes involved are anthropophilic. *T. violaceum* is the most frequent with 59, 4 % of cases. Other species as *T. schoenleinii*, *T. rubrum*, *M. canis* may also be found [3].

The high prevalence of familial cases strongly suggests a Mendelian transmission that has been confirmed by the identification of a homozygous mutation of the CARD9 gene (caspase recruitment domain-containing protein 9) [12]. In 2013, multiples patients with deep dermatophytosis from different countries (Morocco, Algeria and Tunisia) were screened and had an autosomal recessive CARD9 mutation [13]. The mutation leads to a CARD9 protein deficiency affecting T cells and Interleukine 6 and 9 secretion. As a consequence, the immune response to dermatophytic infection is altered with patient becoming more tolerant to dermatophytes and allowing it to invade the dermis and viscera. Untreated, deep dermatophytosis evolves to become life-threatening. Our patient had no history of consanguinity and there were no similar cases in his family but presented a CARD9 deficiency. All the routine blood tests, HIV serology and immunoglobulin quantitation were normal. An acquired mutation seems the more likely in this context.

There is no therapeutic consensus for deep dermatophytosis. Usually, treatment is based on terbinafine or azole derivatives [3; 14]. Itraconazole and Amphotericin B therapy may also show remarkable efficacy [15]. Our patient responded well to Terbinafine at the doses of 500mg a day. Duration of the treatment goes from several months to years and depends of how each patient responds. Resistance and dependence to treatment are common. When possible, surgical excisions of nodules improve the response to treatment [7]. Improvement of the immune response using immuno-modulatory therapy as interferon-gamma therapy [5; 7] could also be a promising therapeutic pathway.

### Conclusion

Deep dermatophytosis is a rare and potentially life-threatening disease. The diagnosis is often delayed due to poor knowing of this uncommon condition. The physiopathology is still unclear and thorough studies are needed to provide answers. A codified therapy should be established. Mutations identifying could open new therapeutic pathways and early diagnosis.

### References

1. Hassam B, Senouci K, Bennouna F, Lazrak B, Agoumi A (1992) Maladie dermatophytique : approche épidémiologique. Médecine du Maghreb 1992 ; 35.
2. Schousboe A. Aspects de la Maladie Dermatophytique 4: 106-108.
3. Cheikhrouhou F, Makni F, Ayadi A (2010) La maladie dermatophytique: revue de la littérature 20 : 61-69.
4. Liautaud B MF, F G Marill (1984) La maladie dermatophytique. Observations algériennes récentes. Bull. la Société Pathol. Exot 77 : 637-648.
5. Abdelmalek R, Mebazaa A, Kilani B, Kanoun F, El Euch D (2010) et.al La maladie dermatophytique: À propos d'un cas clinique 20 : 218-222.
6. Souissi A, Ezzine Sebai N, Benmously R I Mokhtar, B Fazaa,

- 
- E Chaker (2005) et al. La maladie dermatophytique : à propos d'une observation familiale tunisienne 65: 482-6.
  7. Souissi A, Karray M, Chelly I, Zehani A, Hafsi W (2017) et al. Maladie dermatophytique : à propos d'un cas 38: 218-219.
  8. Hironaga M, Okazaki N, Saito K, Watanabe S (1983) Trichophyton mentagrophytes granulomas. Unique systemic dissemination to lymph nodes, testes, vertebrae, and brain 119: 482-90.
  9. Ebongo CN, Hali F, Chihab S (2016) Maladie dermatophytique de révélation tardive 24: 1-6.
  10. Boudghène Stambouli O, Mérad Boudia A (1996) Evolution fatale d'une maladie dermatophytique 6 : 139-141.
  11. Boudghène-Stambouli O (1991) La maladie dermatophytique en Algérie 118: 17-21.
  12. Glocker EO, Hennigs A, Nabavi M, Schäffer AA, Woellner C (2009) et al. A Homozygous CARD9 Mutation in a Family with Susceptibility to Fungal Infections 61: 1727-1735.
  13. Lanternier F, Pathan S, Vincent QB, Liu L, Cypowyj S (2013) et al. Deep Dermatophytosis and Inherited CARD9 Deficiency 369: 1704-1714.
  14. Jachiet M, Lanternier F, Rybojad M, Bagot M, Ibrahim L (2015) Posaconazole treatment of extensive skin and nail dermatophytosis due to autosomal recessive deficiency of CARD9 151: 192-194.
  15. Amrani N, Dahmani B, Boudghene Stambouli O (2015) La maladie dermatophytique avec déficit autosomique récessif en CARD 9 et efficacité spectaculaire de l'itraconazole 142: 597.

**Copyright:** ©2021 Khallaayoune M, et al. This is an open-access article distributed under the terms of the Creative Commons Attribution License, which permits unrestricted use, distribution, and reproduction in any medium, provided the original author and source are credited.