

**Case Report**
**Open Access**

## Elconyxia Induced by Isotretinoin: Myth or Reality?

Ayala Gonzales Melany Liza<sup>1\*</sup> and Diez De Medina Duran Juan Carlos<sup>2</sup>

<sup>1</sup>Dermatologist, La Paz, Bolivia

<sup>2</sup>Private Dermatologist, Skin Foundation, La Paz, Bolivia

### ABSTRACT

Elconyxia is a rare nail disorder reported in the literature, associated with conditions such as peritonitis, psoriasis, syphilis, reactive arthritis, trauma, or retinoid use. Elconyxia due to isotretinoin or oral retinoids is an uncommon, dose-dependent entity that includes onychoschizia, transverse leukonychia, onychorrhexis, pyogenic granuloma, onychocryptosis, median canaliform dystrophy (Heller's dystrophy), and paronychia with onychoschizia being the most common clinical manifestation. These signs are not seen with topical retinoids. Nail plate changes typically begin 3 to 4 months after starting the drug, may affect one or all nails, and are potentially reversible once the medication is discontinued. We report a new case in the literature of a male patient with elconyxia secondary to oral retinoids, with full symptom reversal after completing treatment.

### \*Corresponding author

Ayala Gonzales Melany Liza, Dermatologist, La Paz, Bolivia.

**Received:** May 30, 2025; **Accepted:** June 05, 2025; **Published:** June 11, 2025

**Keywords:** Elconyxia, Onychoschizia, Isotretinoin, Reversible

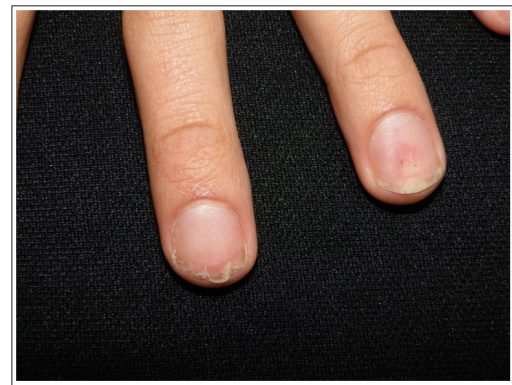### Introduction

Isotretinoin is the most effective retinoid for nodulocystic acne. Its adverse effects are related to its keratinization mechanism and are broad, including mucocutaneous, neuromuscular, psychiatric, teratogenic effects, as well as cheilitis, xerosis, and dermatitis [1-3]. The effects of retinoids on nails are well documented; however, the exact mechanism of damage to the nail bed is not fully understood [1]. Nail changes have been observed starting from the third to fourth month of oral treatment, unlike topical retinoids [2]. Elconyxia is a rare nail disorder reported in association with conditions like peritonitis, psoriasis, syphilis, reactive arthritis, trauma, or retinoids [1].

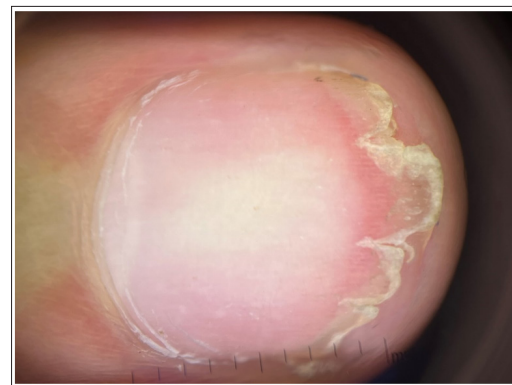This report presents a new case of elconyxia secondary to isotretinoin use.

### Case Report

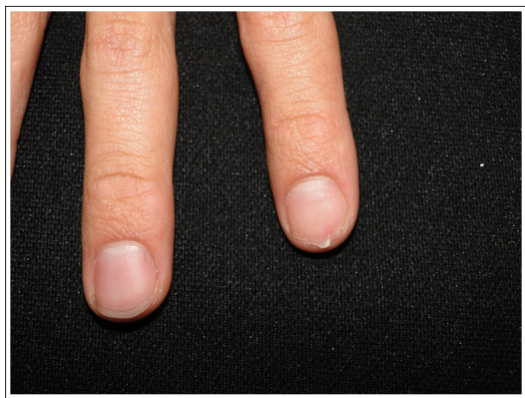A 24-year-old male from La Paz, Bolivia, with a history of nodulocystic acne, was undergoing treatment with isotretinoin 40 mg/day. After two months, he reported brittle nails. He denied any trauma, manual labor, or systemic diseases such as psoriasis. Dermatological examination revealed onychoschizia on the third finger of the left hand, the second finger of the right hand, and leukonychia with a few splinter hemorrhages on the fourth finger of the left hand (Figures 1-4). The full course of isotretinoin treatment was completed, and after 4 to 6 months, the nails returned to normal appearance.



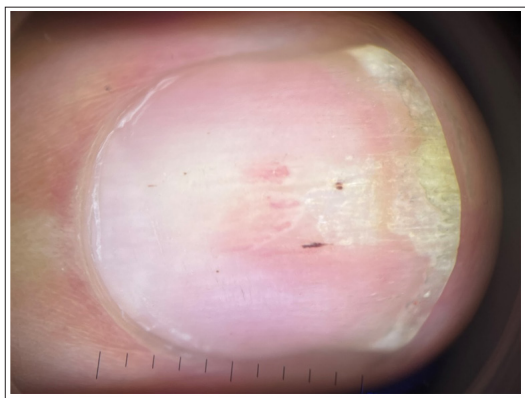
**Figure 1:** Separation of the distal edge of the nail on the third finger of the left hand (onychoschizia) is observed, associated with leukonychia and splinter hemorrhage on the nail plate of the fourth finger of the same hand.



**Figure 2:** On onychoscopy, distal detachment of the nail plate is observed



**Figure 3:** Onychoschizia is observed on the second finger of the right hand



**Figure 4:** Onychoscopy: Leukonychia and splinter hemorrhages on the nail plate

### Discussion

Nail abnormalities are common adverse reactions caused by the administration of various drugs. Symptoms usually depend on acute toxicity and can affect one or several nails, resolving after discontinuation of the medication [4].

Elconyxia is a nail disorder characterized by fragility, dystrophy, loss of nail substance, depressions, and even nail plate fracture. Elconyxia induced by isotretinoin is a rare, dose-dependent condition that includes onychoschizia, transverse leukonychia, onychorrhexis, pyogenic granuloma, onychocryptosis, median canaliform dystrophy (Heller's dystrophy), and paronychia. The most frequently reported findings are onychoschizia due to increased nail growth rate and thinning and paronychia [1-5]. Topical retinoids are only associated with side effects such as Beau's lines, onycholysis, and leukonychia [2,6].

Although further studies are needed, most indicate that these effects are dose-dependent [2]. Some authors also report increased nail growth in patients treated with isotretinoin and a decrease in nail thickness over time, although other literature contradicts this [4,5,7].

### Conclusion

Elconyxia due to isotretinoin is an increasingly reported effect in the literature related to oral retinoids. Dermatologists who prescribe these drugs for extended periods should inform patients about potential side effects affecting the nail plate, which are reversible upon discontinuation of the medication.

### References

1. Allegue F, Gonzalez D, Zulaica A (2017) Elconyxia por isotretinoína. *Carta Científico Clínica* 2: 1.
2. Yiğit Dilek, Karaosmanoğlu, Nermin (2024) Nail Changes in Patients Receiving Systemic Isotretinoin Therapy. *Research Square* 14: 1.
3. Piraccini B, Iorizzo M (2007) Drug Reactions Affecting the Nail Unit: Diagnosis and Management. *Dermatol Clin* 25: 215-221.
4. Yung A, Johnson P (2005) Isotretinoin-induced elconyxia. *British Journal of Dermatology* 153: 664-699.
5. Özçelik S Kılıç FA (2021) Effects of isotretinoin on the growth rate and thickness of the nail plate. *Int J Dermatol* 60:1258-1262.
6. Gregoriou S, Banaka F, Rigopoulos D (2016) Isotretinoin-induced transverse leukonychia. *J Eur Acad Dermatol Venereol* 30: 385-386.
7. Blasiak RC, Stamey CR, Burkhart CN, Lugo-Somolinos A, Morrell DS (2013) Tratamiento con isotretinoína en dosis altas y la tasa de reintento, recaída y efectos adversos en pacientes con acné vulgar. *JAMA Dermatol* 149: 1392-1398.

**Copyright:** ©2025 Ayala Gonzales Melany Liza, et al. This is an open-access article distributed under the terms of the Creative Commons Attribution License, which permits unrestricted use, distribution, and reproduction in any medium, provided the original author and source are credited.