

Case Report
Open Access

Primar Urinary Bladder Endometriosis: Laparoscopic Approach towards Therapeutic Mapping

Sofoudis Chrisostomos^{1*}, Papadopoulos Zacharias², Sotiriou Vasilis³ and Zioris Konstantinos²

¹Department of Obstetrics and Gynecology, Konstandopoulio General Hospital, Athens, Greece

²Department of Obstetrics and Gynecology, Mitera, Maternal Hospital Athens, Greece

³Department of Urology, Hygeia, General Hospital, Athens, Greece

ABSTRACT

Endometriosis of genital tract consists a controversial entity arising from current bibliography.

Many conducted studies suggested a variety of pathophysiologic mechanisms in order to establish proper diagnosis and treatment. In many cases development of endometrial tissue outside endometrial cavity, can lead to depiction of physical symptomatology with unexpected clinical route. Besides, dysmenorrhea, dyspareunia and decrease of fertility capability, endometriosis can infiltrate many intraperitoneal organs such as urine bladder, rectum, or even mesenterium and lungs. Primary bladder endometriosis represents a very rare entity among female reproductive patients. Ultimate scope remains fertility preservation and increase of patient's quality of life.

Aim of our study reflects assiduous diagnosis and depiction of proper therapeutic strategy.

*Corresponding author

Chrisostomos Sofoudis, Department of Obstetrics and Gynecology, Konstandopoulio General Hospital, Athens, Greece. E-mail: chrisostomos.sofoudis@gmail.com

Received: June 21, 2021; **Accepted:** June 27, 2021; **Published:** June 30, 2021

Keywords: Urine bladder, Endometriosis, Hematuria

Introduction

Endometriosis consists one of the most common pathology among women of reproductive age.

Many conducted studies throughout current bibliography did not manage to depict accurate pathophysiologic mapping. Many theories accomplish to compose as gynecologic entity, the existence and production of endometrial tissue outside endometrial cavity [1]. Endometriosis represents a debilitating disease with features of chronic inflammation. Global incidence estimates around 10-15% in women of reproductive age [2]. Most common anatomic locations of peritoneal infiltration consist the ovaries, the fossa ovarica, the uterosacral ligaments and the posterior cul-de-sac [3]. Classification is focused on the severity of clinical symptoms, depth of invasion, number of anatomic locations [4]. Besides, dysmenorrhea, dyspareunia and decrease of fertility capability, endometriosis can infiltrate many intraperitoneal organs such as urine bladder, rectum, or even mesenterium and lungs [5]. Pathologic infiltration of endometrial glands and tissue in anatomic areas outside endometrial cavity can affect the hormonal and functional balance of female reproductive system and fertility preservation as well. Therapeutic strategy is focusing on pharmaceutical or conservative surgical intervention with

ultimate scope the patient's fertility preservation.

Case

A 37-year-old female patient (G2, P2) admitted at our Department, complaining of episodes of diffuse abdominal pain and hematuria. Physical examination revealed tenderness in the lower anatomic area, especially in the left region. Transvaginal ultrasonography depicted area maximal diameter 3cm infiltrated the upper layer of the urine bladder fully covered with hemorrhagic elements compatible with endometriotic lesion. Pap smear negative for malignancy. Abdominal MRI presented area maximal diameter 2cm subserosal, in the upper uterine layer compatible with adenomyosis. In the upper area of urine bladder second area maximal diameter 3,3X2X2, 8cm with infiltrated characters, penetrating all anatomic layers, fully covered with cystic and micro-hemorrhagic elements compatible with endometriosis. Cul de sac free of malignancy. No signs of infiltrated inguinal lymph nodes.

Due to depiction of imaging findings and physical examination, considered mandatory for the patient to underwent laparoscopic dissection of the lesion. Cystoscopic evaluation confirmed all imaging findings. Setting of bilateral pigtailed along the ureteral length. (Figure I, II)

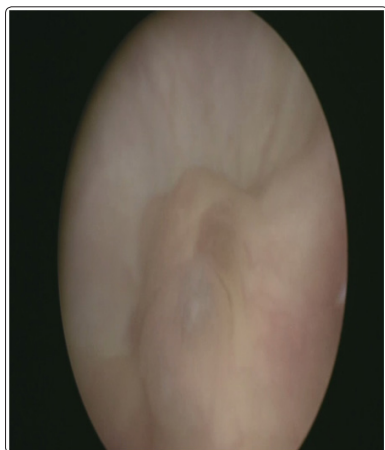


Figure I: Cystoscopic performance of endometriotic lesion

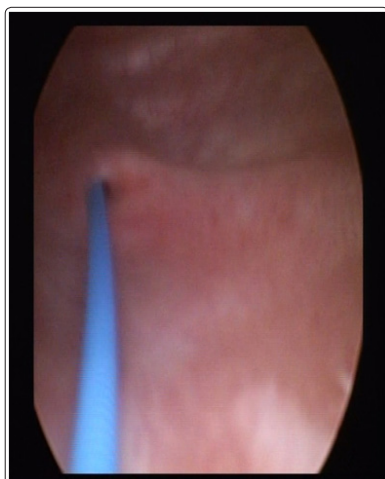


Figure II: Pigtail setting

Penetrating the peritoneal cavity, setting of pneumoperitoneum and all appropriate trocars, identification of area maximal diameter 3cm in the Retzius space, infiltrating all urine bladder layers. Patient underwent laparoscopic dissection of the endometriotic area, followed by assiduous suturing. (Vicryl 3.0 constant accompanied with burial stiches)(Figure III)

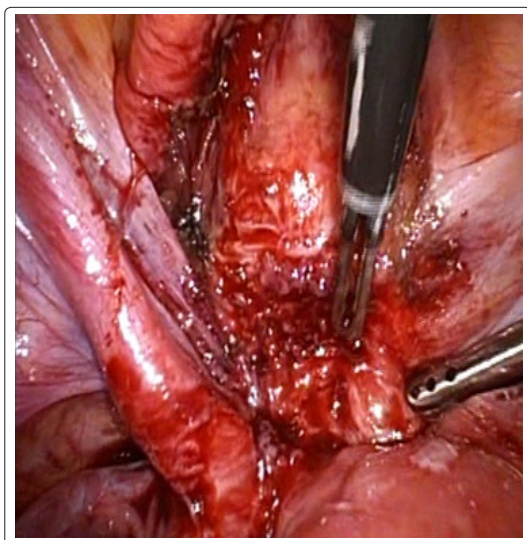


Figure III: Laparoscopic dissection of endometriotic lesion

Allowance of 180 ml methylene blue through the urine catheter in order to ensure the elasticity of the bladder. Patient discharged

hospital next pod in good clinical condition. Follow up did not depict signs of recurrence. Pigtailes removal in the following six months, did not reveal decrease of the lesion.

Discussion

Urine tract endometriosis consists infiltration of urine bladder and along the anatomic length of the ureter, entering the renal epithelium. Global incidence estimates about 1% of endometriotic cases, with majority of them depicting urine bladder with incidence of 85% [6]. Pathogenic approach reflects local skip or expansion of endometrial stroma and glands isolated beneath incisional scars following caesarian sections into urine endothelium [7]. In young female patients of reproductive age, optimal therapeutic strategy consists ultimate scope depending on the stage of the lesion and the severity of clinical symptomatology. After the establishment of clinical diagnosis, therapeutic mapping divides into surgical and non-surgical intervention [8].

Surgical intervention is strongly accompanied with severity of clinical symptomatology. Diffuse abdominal pain and episodes of hematuria, consists surgical dissection mandatory. Bladder cystectomy followed by assiduous suturing closure in two layers of the bladder cavity represents the most common surgical method. Non-surgical treatment as examples of pharmacologic agents such as oral contraceptives, GnRH antagonists, progesterone receptor modulators, antiestrogens, can be helpful as postoperative methods [9]. Primar urine bladder endometriosis consists a rare clinical entity with persistent clinical status, influencing the daily routine of these patients, taking into severe consideration the clinical intervention.

Disclosure of Interest

All authors declare any financial interest with respect to this manuscript.

Conclusion

Endometriosis consists one of the most common gynecologic entities among women of reproductive age. Pathologic infiltration of endometrial glands and tissue in anatomic areas outside endometrial cavity can affect the hormonal and functional balance of female reproductive system and fertility preservation as well. Disciplinary approach is mandatory in order to establish an ultimate therapeutic mapping.

References

1. Mehedintu C, Plotogea MN, Ionescu S, Antonovici M (2014) Endometriosis still a challenge. *J Med Life*. 7: 349-357.
2. Buck Louis GM, Hediger ML, Peterson CM, Croughan M, Sundaram R, Stanford J, Chen Z, Fujimoto VY, Varner MW, Trumble A, Giudice LC (2011) ENDO Study Working Group. Incidence of endometriosis by study population and diagnostic method: the ENDO study. *Fertil Steril*. 96: 360-365.
3. Lee HJ, Park YM, Jee BC, Kim YB, Suh CS (2015) Various anatomic locations of surgically proven endometriosis: A single center experience. *Obstet Gynecol Sci*. 58: 53-58.
4. Rolla E (2019) Endometriosis: advances and controversies in classification, pathogenesis, diagnosis, treatment. <https://pubmed.ncbi.nlm.nih.gov/31069056/>.
5. Brady PC, Missmer SA, Laufer MR (2017) Bladder involvement in stage I endometriosis. *J Pediatr Adolesc Gynecol*. 30: 503-504.
6. Sevellaraja S, Eng T K (2020) Laparoscopic bladder cystectomy for bladder endometriosis: A combined cystoscopic and laparoscopic approach. *J Minim Invasive Gynecol*. 27: 575-576.

-
7. Shalin SC, Haws AL, Carter DG, Zarrin-Khameh N (2012) Clear cell carcinoma arising from endometriosis in abdominal wall cesarean section scar: a case report and review of the literature. *J Cutan Pathol.* 39: 1035-1041.
 8. Gustilo-Ashby AM, Paraiso MF (2006) Treatment of urine tract endometriosis. *J Minim Invasive Gynecol.* 13: 559-565.
 9. Benagiano G, Guo S, Bianchi P, Puttemans P, Gordts S, Petraglia F, Brosens I (2016) Pharmacologic treatment of ovarian endometrioma. *Expert Opin Pharmacother.* 17: 2019-2031.

Copyright: ©2021 Chrisostomos Sofoudis, et al. This is an open-access article distributed under the terms of the Creative Commons Attribution License, which permits unrestricted use, distribution, and reproduction in any medium, provided the original author and source are credited.