

## Case Report

## Open Access

# A Case Report of Cystinuria with Anuria as the First Symptom and Literature Review

Jie Kong<sup>1</sup>, Jin-Feng Wu<sup>1</sup>, Man-Cheng Gong<sup>2</sup>, Mei Qiu<sup>3\*</sup> and Run-Qiang Yuan<sup>1,2\*</sup>

<sup>1</sup>Guangdong Medical University, Zhanjiang, 524023, Guangdong, China

<sup>2</sup>Department of Urology, Zhongshan People's Hospital, Zhongshan, 528404, China

<sup>3</sup>Shanghai Changzheng Hospital, 200003, Shanghai, China

## ABSTRACT

Patients with urinary stones typically present to the doctor with hematuria, low back pain, and abdominal pain. This paper reports a case of cystinuria with anuria as the first symptom. The patient's initial blood test showed creatinine of 2028.70 $\mu$ mol/L and uric acid of 1072.65 $\mu$ mol/L, and a CT scan showed both kidneys and ureters full of stones. The patient underwent hemodialysis, bilateral renal puncture fistulas, and multiple PCNL and flexible ureteroscopic laser lithotripsy to crush stones. Post-operative review creatinine of 138.08 $\mu$ mol/L, uric acid of 230.00 $\mu$ mol/L, and a CT scan showed clearance of the stones, and compositional analysis of the stones showed that they consisted exclusively of cystine. After undergoing postoperative hydration, urinary alkalization, and an animal protein intake restriction, the patient's condition became better and there has been no recurrence of the stones. Patients with this kind of disease should be identified, diagnosed, and prevented at an early stage in order to reduce the number of surgeries and preserve renal function. Cystinuria is prone to recurrence, which can lead to urinary tract obstruction and urinary tract infection, which raises the risk of acute and chronic renal disease.

## \*Corresponding author's

Run-Qiang Yuan, Department of Urology, Zhongshan People's Hospital, 528404, Zhongshan, China.

Mei Qiu, Shanghai Changzheng Hospital, 200003, Shanghai, China.

**Received:** April 10, 2025; **Accepted:** April 14, 2025; **Published:** April 25, 2025

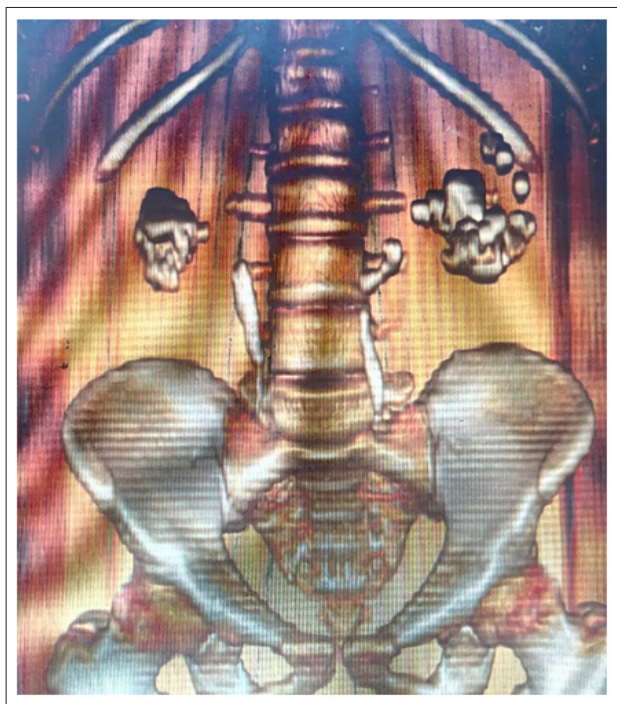**Keywords:** Cystinuria, Cystine Stones, Acute Kidney Injury, Dietary Management, GSMV Position

## Introduction

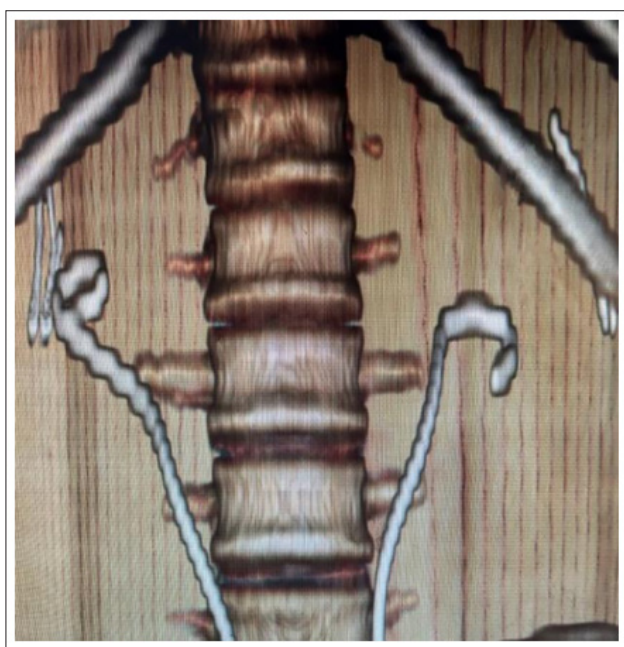
It is currently thought that the genes SLC3A1 and SLC7A9 were the causes of cystinuria, an autosomal recessive disorder characterized by the defective reabsorption of cystine and the basic amino acids ornithine, lysine, and arginine in the proximal renal tubules [1]. This caused crystal precipitation and cystine stone formation in the distal tubules because patients with the disease excrete a lot of cystine and it is poorly soluble at normal urine power of Hydroge (pH). Just 1% of urolithiasis cases were caused by cystine stones, and the majority occur during childhood or adolescence. The diagnosis of cystinuria can be made by genetic testing, cystine crystal observation in the urine sediment, aberrant cystine excretion in the urine, or stone composition analysis [2].

On March 7, 2023, the patient presented to the nephrology department with "edema of both lower limbs and face with anuria for 3 days". The patient had no weakness of limbs, no foamy urine, no nausea and vomiting, no fever, no lumbar pain or lumbar distension, and at the time of admission, creatinine of 2028.70 $\mu$ mol/L, uric acid of 1072.65 $\mu$ mol/L, urinary leukocytes of "++", and urinary pH of 7.50. A physiological examination was performed on the following subjects: T: 36.3°C, P: 103beats/min, BP: 159/112 mmHg, BMI: 21.36. Slight percussion pain in both renal regions; no pressure pain. Past health were average, there were no family history of stones.

After admission, he was given hemodialysis, sodium bicarbonate to alkalize the urine, and blood sampling to exclude primary hyperparathyroidism and other metabolic disorders. According to CT scan results (Figure 1), both kidneys had staghorn-shaped stones and multiple stones in both ureters, and both kidneys were hydronephritic, with a CT value of about 689HU, with perirenal exudate and subcutaneous soft tissue edema of the abdominal and pelvic walls. He underwent a bilateral percutaneous nephrostomy to relieve the obstruction after being admitted to our department on March 11, 2023. His blood pressure dropped to 114/70mmHg and his urine production increased from 0 to 1920mL in only one day. In the course of the hospital stay, four rounds of percutaneous nephroscopic laser lithotripsy with the original channel were performed, along with transurethral flexible ureteroscopic laser lithotripsy. During the last surgery, endoscopic combined intrarenal surgery with flexible ureteroscopic lithotripsy was performed in the galadakao-modified supine valdivia (GMSV) posture [3]. The composition analysis of the urine suggested that the stones were cystine, and the postoperative CT follow-up showed (Figure 2) that the two renal ureteral stones had been removed, with a creatinine level of 138.08 $\mu$ mol/L and a uric acid level of 230.00 $\mu$ mol/L. At the time of discharge, the patient was directed to take 2.5g of sodium hydrogen potassium citrate granules orally three times a day plus 2.5g at night for the rest of their lives. Additionally, the urine pH level should be kept between 7.0 and 8.0, and the urinary CT was scheduled for routine follow-up examinations. A year following the procedure, no recurrence of stones was seen during the CT scan.



**Figure 1:** Both Kidneys had Staghorn-Shaped Stones and Multiple Stones in Both Ureters



**Figure 2:** The Two Renal Ureteral Stones had been Removed

## Discussion

Due to the extraordinary rarity of cystine stones, most urologists are unaware of the condition, particularly regarding its recurrence, which can lead to an increased need for surgeries and a higher risk of end-stage renal disease development in patients [4]. Thus, it is important to obtain a thorough family history, enhance our understanding of the urinary calculi's composition, and, if feasible, conduct genetic testing when dealing with young patients who have a history of repeated recurring stones and a hereditary susceptibility to stones in their families [5].

According to the European Association of Urology guidelines for urologic stones, cystine stones are treated in the same way as other renal stones, with retrograde intrarenal surgery (RIRS) recommended as the first-line treatment for <2cm renal stones and percutaneous nephrolithotomy recommended as the gold standard for ≥2cm renal stones [6,7]. However, for complex renal stones, especially dextrorotational stones, multiple percutaneous nephroscopic lithotripsy procedures are required to achieve a high stone-free rate (SFR), and the complications associated with the procedure increase. There has been a gradual breakthrough in the treatment paradigm for large and/or complex renal stones, and RIRS is no longer considered an adjunctive or alternative approach but rather an essential component in conjunction with percutaneous nephroscopic lithotripsy, which helps to reduce operative time and additional complications to better protect renal function [8,9]. Due to the high recurrence rate and rapid growth rate of cystine kidney stones, patients often require multiple surgical treatments during their lifetime, and when PCNL is performed, it is suggested that the use of newer miniaturization techniques may help to reduce trauma to the renal parenchyma and shorten the time to placement of ureteral stents in patients with recurrent stones [9].

Current guidelines recommend increasing water intake to at least 2.5 L/day to prevent stone formation and even up to 3.5–4L for cystine stones to keep cystine concentrations below 250mg/L (1mmol/L) [6]. To prevent oversaturation of the urine at night, fluid intake must be balanced throughout the day and night. Alkaline drinks raise the pH of the urine and enhance the excretion of citrate; as a result, patients with cystinuria are advised to drink alkaline beverages such as mineral water rich in bicarbonate [10]. It is recommended that all patients with cystinuria self-monitor their urine pH in order to maintain it between 7.5 and 8. Smartphone apps can be used to track and remind users to drink water each day. Potassium hydrogen citrate medication is commonly used to alkalize the urine and increase cystine solubility. When patients have severe renal insufficiency or an intolerance to potassium hydrogen citrate, sodium bicarbonate is usually advised. In cases of refractory cystinuria, where stones still form despite excessive alkaline hydration, thiopronin or D-penicillamine is added [2]. I-Ergothioneine, an antioxidant, has recently been suggested as a potential novel treatment for cystinuria, though routine clinical use of this medication has not yet been established [11].

Although cystine reabsorption is not directly dependent on sodium, a high-sodium diet can impede cystine apical reabsorption. The recommended sodium chloride intake is 6 g/day, and in addition, reduced intake of methionine-rich foods may reduce cystine production [12].

## Author Contributions

Jie Kong contributed to the case report, statistical analysis, and manuscript. Jin-feng Wu and Man-cheng Gong contributed to the discussion and the revision of the manuscript. Run-qiang Yuan and Mei Qiu contributed to the case administration. All authors read and approved the final manuscript.

## Declaration of Competing Interest

All authors declared that they have no competing financial interests or personal relationships that could have appeared to influence the work reported in this paper.

## Funding

Key Medical Specialty Project of Zhongshan People's Hospital (T2023022); Major Public Welfare Science and Technology Research Project of Zhongshan City (K2021B3013).

## References

1. D'Ambrosio V, Capolongo G, Goldfarb D, Gambaro G, Manuel Ferraro P (2022) Cystinuria: an update on pathophysiology, genetics, and clinical management. *Pediatr Nephrol* 37: 1705-1711.
2. Servais A, Thomas k, Dello Strologo L, Sayer SA, Bekri S, et al. (2021) Cystinuria: clinical practice recommendation. *Kidney Int* 99: 48-58.
3. Scoffone CM, Cracco CM, Cossu M, Grande S, Poggio M, et al. (2008) Endoscopic combined intrarenal surgery in Galdakao-modified supine Valdivia position: A new standard for percutaneous nephrolithotomy? *Eur Urol* 54: 1393-1403.
4. Kellum JA, Romagnani P, Ashuntantang G, Ronco C, Zarbock A, et al. (2021) Acute kidney injury. *Nat Rev Dis Primers* 7: 52.
5. Nalcacioglu H, Ozden E, Genc G, Yakupoglu YK, Sarikaya S, et al. (2013) An uncommon cause of acute kidney injury in young children: cystinuria. *J Pediatr Urol* 9: e58-e63.
6. Türk C, Petřík A, Sarica K, Seitz C, Skolarikos A, et al. (2016) EAU Guidelines on Diagnosis and Conservative Management of Urolithiasis. *Eur Urol* 69: 468-474.
7. Türk C, Petřík A, Sarica K, Seitz C, Skolarikos A, et al. (2016) EAU Guidelines on Interventional Treatment for Urolithiasis. *Eur Urol* 69: 475-482.
8. Setthawong V, Srisubat A, Potisat S, Lojanapiwat B, Pattanittum P, et al. (2023) Extracorporeal shock wave lithotripsy (ESWL) versus percutaneous nephrolithotomy (PCNL) or retrograde intrarenal surgery (RIRS) for kidney stones. *Cochrane Database Syst Rev* 8: CD007044.
9. Wen J, Xu G, Du C, Wang B, et al. (2016) Minimally invasive percutaneous nephrolithotomy versus endoscopic combined intrarenal surgery with flexible ureteroscope for partial staghorn calculi: A randomised controlled trial. *Int J Surg* 28: 22-27.
10. Courbebaisse M, Travers S, Boudierlique E, Michon-Colin A, Daudon M, et al. (2023) Hydration for Adult Patients with Nephrolithiasis: Specificities and Current Recommendations. *Nutrients* 15: 4885.
11. Mayayo-Vallverdú C, López De Heredia M, Prat E, González L, Guarch ME, et al. (2023) The antioxidant l-Ergothioneine prevents cystine lithiasis in the Slc7a9<sup>-/-</sup> mouse model of cystinuria. *Redox Biol* 64: 102801.
12. Ucmak H, Sonmez MG, Guven S (2023) Case-based review of dietary management of cystinuria. *World Journal of Urology* 41: 1215-1220.