

Case Report

Open Access

Rapid and Remarkable Response of Deep Second-Degree Burns to the Herbal Oils “Kadi” Product of a Yemeni Child: A Case Report

Hussien O Kadi^{1*}, Ismail Hamoud Ali Al-geobri², Mohammed H Kadi³ and Taha Hussien K²

¹Sanaa University, Faculty of Medicine and Health Sciences, Sanaa, Yemen

²Yemen University, Faculty of Medical Sciences, Sanaa, Yemen

³Yemen University, Faculty of Medical Sciences, 48 Hospital, Sanaa, Yemen

ABSTRACT

Background: Pediatric burns are a common injury, posing significant challenges due to the risk of infection and long-term scarring. The search for effective, safe, and easily accessible topical treatments is crucial, especially in resource-limited settings.

Case Presentation: A 10-year-old Yemeni male presented with a deep partial-thickness burn on his forearm caused by hot tea (scald). Initial conventional treatments, including Mebo® ointment, povidone-iodine debridement, and topical Fucidin® (fusidic acid) for infection prophylaxis, failed to promote satisfactory healing. The treatment regimen was then switched to a novel topical application of the mix herbal extract oils, “Kadi”, applied three times daily.

Outcomes: A dramatic clinical response was observed immediately following the initiation of Kadi herbal oils drops product. The wound achieved complete re-epithelialization within seven days of Kadi application, which is significantly faster than expected for this burn depth. The final outcome demonstrated excellent cosmetic results with minimal post-inflammatory hyperpigmentation and the absence of hypertrophic scarring.

Conclusion: This case report demonstrates the outstanding and rapid efficacy of the topical herbal extract Kadi herbal oils drops product in treating deep partial-thickness burns in children. Kadi herbal oils drops product presents itself as a highly promising alternative or adjunct therapy for burn management, warranting further randomized controlled trials (RCTs) to elucidate its active components and mechanism of action.

*Corresponding author

Hussien O Kadi, Sanaa University, Faculty of Medicine and Health, Yemen.

Received: April 03, 2026; **Accepted:** April 07, 2026; **Published:** April 28, 2026

Keywords: Kadi, Herbal, Oils, Burn, Treatment

Introduction

Burns are considered among the most severe forms of physical trauma. Such injuries can lead to significant physical disabilities as well as psychological and emotional disorders. In low-income nations, burns constitute a prominent public health concern [1]. The World Health Organization (WHO) has documented that annually, approximately 11 million individuals around the globe experience burn injuries. Of these, roughly 180,000 fatalities occur as a direct consequence of these injuries, and non-fatal burn injuries represent a major contributor to morbidity rates [2]. The preponderance of these incidents is observed in low- and middle-income nations within the African and South-East Asian regions [2]. Deep partial-thickness (second-degree) burns involve the epidermis and extend deep into the dermis, requiring prompt and effective management to prevent wound infection and minimize the risk of developing disfiguring scars, such as hypertrophic scars and keloids [3].

Standard treatment protocols aim for rapid wound closure and typically involve wound cleaning, debridement (often with

solutions like povidone-iodine), topical antimicrobial agents (e.g., silver sulfadiazine, fusidic acid), and wound-healing enhancing ointments (e.g., Mebo). However, when conventional methods result in slow healing, alternative therapies, particularly those derived from traditional herbal medicine, are often sought [4].

Cutaneous burns represent one of the most formidable challenges within the realm of medical science. Investigations have been focused on the innovation of natural products aimed at discerning efficacious and safe therapeutic interventions [4]. Curcumin emerges as a promising phytochemical for the management of hyperinflammatory burn injuries, functioning through the attenuation of TNF- α and IL-1 synthesis by human macrophages, thus exhibiting notable anti-inflammatory properties [5,6]. Furthermore, curcumin inhibits the proliferative pathways associated with keloids and hypertrophic scar-derived fibroblasts [6]. Research involving human subjects has corroborated the therapeutic efficacy of *A. vera* in patients suffering from second-degree burn wounds [7]. *A. vera* is characterized by its anti-inflammatory, antibacterial, and antiseptic properties, alongside its demonstrated capacity to promote collagen synthesis during

the wound healing process. Certain species of Terminalia have been documented to possess wound-healing attributes, as well as antioxidant and antimicrobial activities, accompanied by anti-inflammatory effects [8]. Pomegranate (*P. granatum*) is considered a potential antioxidant therapy for enhancing burn wound healing [9]. Similarly, sesame oil and chamomile oil have demonstrated promising effects in burn treatment, owing to their anti-inflammatory, antioxidant, and skin-regenerating properties. Research indicates that these oils can alleviate pain, promote faster wound healing, reduce swelling, and enhance both skin thickness and hair follicle regeneration [10,11]. Further studies have also highlighted the effectiveness of combining sesame oil with pumpkin in varying concentrations to accelerate the healing process of burn injuries [12].

This report documents the compelling case of a pediatric patient whose deep second-degree burn, refractory to standard care, achieved surprisingly rapid and complete healing following the introduction of the local herbal preparation, Kadi herbal oils product.

The hypothesis of new formulation of Kadi herbal oils drops product contain mixture of some natural herbal oils with different amounts for each one which was done by Prof. Dr. Hussien O. Kadi and Ismail Hamoud Ali Al-geobri (Patent).

Case Presentation

A healthy 10-year-old male patient from Yemen sustained a scald injury to his right forearm after hot tea was accidentally spilled. Clinically, the burn was classified as a deep partial-thickness burn, characterized by a mixed pattern of erythema, partial blistering, and areas of pale, blanching skin, estimated to cover approximately 4% of the Total Body Surface Area (TBSA). Father of the child volunteer gave a written informed consent and the Ethics Committee of Yemen University; Faculty of medical Sciences approved the clinical protocol and have been performed in accordance with the ethical standards as laid down in the 1964 Declaration of Helsinki and its later amendments or comparable ethical standards.

Initial Management and Failure

The initial treatments were administered sequentially over several days:

- **Home Care:** Topical application of Mebo ointment was used immediately following the injury.
- **Clinic Intervention:** Upon presentation to the clinic, the wound was surgically cleaned and debrided using povidone-iodine solution. To prevent secondary infection, topical Fucidin (fusidic acid) was prescribed.
- **Observation:** Despite these interventions, the wound showed slow signs of healing, persisting with erythema and exudation, suggesting a prolonged recovery course and high risk of scarring.

Kadi Herbal Oils Drops Product Treatment and Response

Given the unsatisfactory progression, the treatment was switched to a non-conventional local preparation: the herbal extract oils “Kadi” drops product. The extract was applied topically to the entire burn area three times daily.

Clinical Course

- **Rapid Improvement:** Significant reduction in peri wound erythema and inflammation was noted within the first 48 hours of Kadi application.
- **Complete Healing:** Remarkably, the burn site achieved

complete re-epithelialization within seven days from the start of the Kadi regimen.

- **Final Outcome:** Follow-up confirmed excellent cosmesis. There was no evidence of hypertrophic scarring or keloid formation, only minimal transient post-inflammatory hyperpigmentation.

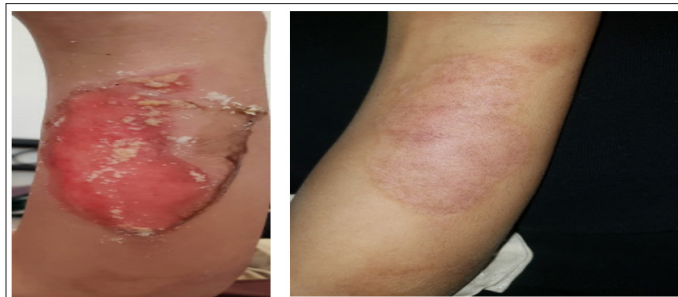


Figure 1: Before

Figure 2: After

Figure 1: Deep Partial-Thickness Burn on Presentation. Image of the right for arm before the application of Kadi, showing erythema and surface irregularity consistent with a deep second-degree burn following initial conventional treatment failure

Figure 2: Complete Healing After Seven Days of Kadi Treatment. Image of the same area showing complete re-epithelialization with minimal residual hyperpigmentation and no evidence of scarring

Discussion

The healing time for deep partial-thickness burns typically ranges from three to six weeks. The observed complete re-epithelialization within seven days following the application of the Kadi is a deviation from the expected clinical course and highlights the potential potent therapeutic properties of this herbal preparation.

The failure of the initial conventional approach (Mebo, Fucidin, debridement) followed by the dramatic success of Kadi suggests that possesses unique and highly effective wound-healing properties, potentially mediated by anti-inflammatory effects which reducing the intensity of the inflammatory phase is critical for accelerating healing and mitigating scarring, angiogenic and proliferative properties [11-14]. The components in Kadi product may stimulate the proliferation and migration of keratinocytes and fibroblasts, essential for the rapid formation of new skin tissue. Antioxidant activity which Minimizing reactive oxygen species (ROS) damage in the wound bed, which is common after burn injury [14-18].

This case provides compelling evidence supporting the role of certain herbal derivatives in regenerative medicine. The minimal scar formation is particularly significant, as scar prevention is the ultimate goal in pediatric burn care. Further phytochemical analysis of Kadi product is warranted to identify the active compounds responsible for this accelerated healing capacity. The present study suggested that natural product may effective as therapeutic agent in skin second degree burns, inflammation and bacterial infection.

Conclusion

This report demonstrates the exceptional clinical efficacy of the herbal extract oils Kadi product in achieving rapid and aesthetically pleasing healing of a deep partial-thickness burn in a pediatric patient where conventional therapies were insufficient. Kadi product should be considered a promising agent in burn management, justifying its rigorous scientific evaluation through future controlled trials.

References

1. Smolle C, Cambiaso-Daniel J, Forbes AA, Wurzer P, Hundeshagen G, et al. (2017) Recent trends in burn epidemiology worldwide: A systematic review. *Burns* 43: 249-257.
2. (2024) Burns fact sheet. World Health Organization.
3. Sharma S, Alfonso AR, Gordon AJ, Kwong J, Lin LJ, et al. (2022) A Meta-analysis and Systematic Review. *Adv Skin Wound Care* Nov 1: 1-9.
4. Jewo PI, Fadeyibi IO, Babalola OS, Saalu LC, Benebo AS, et al. (2009) Comparative Study of the Wound Healing Properties of Moist Exposed Burn Ointment (MEBO) and Silver Sulphadiazine. *Ann Burns Fire Disasters* 30: 79-82.
5. Anis A, Sharshar A, El Hanbally S, Shehata AA (2022) Histopathological Evaluation of the Healing Process of Standardized Skin Burns in Rabbits: Assessment of a Natural Product with Honey and Essential Oils. *Journal of Clinical Medicine* 11: 6417.
6. Song K, Peng S, Sun Z, Li H, Yang R (2011) Curcumin suppresses TGF- β signaling by inhibition of TGIF degradation in scleroderma fibroblasts. *Biochemical and Biophysical Research Communications* 411: 821-825.
7. Tummalapalli M, Berthet M, Verrier B, Deopura BL, Alam MS, et al. (2016) Composite wound dressings of pectin and gelatin with Aloe vera and curcumin as bioactive agents. *International Journal of Biological Macromolecules* 82: 104-113.
8. Shahzad MN, Ahmed N (2013) Effectiveness of Aloe vera gel compared with 1% silver sulphadiazine cream as burn wound dressing in second degree burns. *The Journal of the Pakistan Medical Association* 63: 225-230.
9. Duansak D, Somboonwong J, Patumraj S (2003) Effects of Aloe vera on leukocyte adhesion and TNF-alpha and IL-6 levels in burn wounded rats. *Clinical Hemorheology and Microcirculation* 29: 239-246.
10. Mo J, Panichayupakaranant P, Kaewnopparat N, Nitiruangjaras A, Reanmongkol W (2014) Wound healing activities of standardized pomegranate rind extract and its major antioxidant ellagic acid in rat dermal wounds. *Journal of Natural Medicines* 68: 377-386.
11. Tabatabaei S M, Mohebi Far A, Saremi Z, Zandi M, Aghaei S, et al. (2017) The Effect of Sesame Oil and Cucurbita on Healing Wounds Caused by Third-Degree Burn. *J Skin Stem Cell* 4: e68333.
12. Biswas TK, Mukherjee B (2003) Plant medicines of Indian origin for wound healing activity: A review. *The International Journal of Lower Extremity Wounds* 2:25-39.
13. Arno AI, Amini-Nik S, Blit PH, Al-Shehab M, Belo C, et al. (2014) Effect of human Wharton’s jelly mesenchymal stem cell paracrine signaling on keloid fibroblasts. *Stem Cells Translational Medicine* 3: 299-307.
14. Nigel Tapiwa Mabvuure, Christopher Felix Brewer, Kevin Gervinb, Siobhan Duffy (2020) The use of moist exposed burn ointment (MEBO) for the treatment of burn wounds: a systematic review. *Journal Of Plastic Surgery and Hand Surgery* 54: 337-343.
15. Golledge C (1999) Fusidic acid in other infections. *Int J Antimicrob Agents*. Suppl 2: S11-5.
16. Anshul Sharma, Keshav Dhiman, Anshul Sharma, Kamya Goyal, Vinay Pandit. et al. (2022) Fusidic Acid: A Therapeutic Review. *Asian Journal of Research in Chemistry* 15: 372-0.
17. Ang ESW, Lee ST, Gan CSG, See P, Chan YH, et al. (2000) The Role of Alternative Therapy in the Management of Partial Thickness Burns of the Face-Experience with the Use of Moist Exposed Burn Ointment (MEBO) Compared with Silver Sulphadiazine. *Annals of Academy Journal of Medicine* 29: 7-10.
18. Al-Samydai A, Abu Hajleh MN, Mayyas A, Al-Mamoori F, Al-Tawalbe DM, et al. (2023) Ethnopharmacological Study of Medicinal Plants Used in the Treatment of Skin Burns in the Arab World. *J Burn Care Res* 44: 1216-1222.
19. Aliasl J, Khoshzaban F (2023) Traditional Herbal Remedies for Burn Wound Healing in Canon of Avicenna. *Jundishapur J Nat Pharm Prod* 8: 192-196.

Copyright: ©2026 Hussien O Kadi, et al. This is an open-access article distributed under the terms of the Creative Commons Attribution License, which permits unrestricted use, distribution, and reproduction in any medium, provided the original author and source are credited.