

Case Report

Open Access

Giant Bilateral Adrenal Leiomyoma Case Report

María A Calderón González*, Ana K Mena Zenteno, Isis Silva De la Vega and Alejandra Brindis Soto

General and Gastrointestinal Surgery Department, Hospital General Regional No.1, Santiago de Queretaro, Queretaro, Mexico

ABSTRACT

Introduction: Adrenal leiomyoma is extremely rare and is thought to arise from the smooth muscle wall of the central adrenal vein and its branches; Clinically they may present as abdominal pain or flank pain. These tumors generally have a low biological potential. The surgical indication for adrenal tumors is based mainly on functionality and the risk of malignancy.

Clinical Case: 39-year-old male, with no significant history. Who comes to the general surgery outpatient clinic due to the presence of progressive abdominal distension and long-term abdominal pain. An abdominopelvic CT scan was performed, which revealed bilateral, well-circumscribed tumor with heterogeneous characteristics located in the left and right adrenal area, negative functional tests. An exploratory laparotomy was performed, revealing two giant adrenal tumors, definitive study reporting bilateral adrenal leiomyoma.

Conclusion: We present a rare case of bilateral primary adrenal leiomyoma of which no similar case was found in the reviewed literature. These tumors are very difficult to diagnose preoperatively, as they are often not counted in adrenal samples and clinical suspicion is very low. As a result, they are diagnosed postoperatively after pathological examination of the surgical specimen. At the moment, early and complete surgical resection is the main treatment.

*Corresponding author

María A Calderón González, General and Gastrointestinal Surgery Department, Hospital General Regional no.1, Santiago de Queretaro, Queretaro, Mexico.

Received: August 15, 2024; **Accepted:** August 20, 2024; **Published:** September 30, 2024

Keywords: Adrenal Gland, Bilateral, Leiomyoma, Surgery

Introduction

Tumors of adrenal origin can derive from the cortex or medulla, which depends on the type of functionality they can develop. Adrenal masses have variable forms of presentation. The prevalence of adrenal tumors varies between 1.4 and 8.7%. Adrenal leiomyoma is extremely rare and is thought to arise from the smooth muscle wall of the central adrenal vein and its branches; Clinically they may present as abdominal pain or flank pain. These tumors generally have a low biological potential. The surgical indication for adrenal tumors is based mainly on functionality and the risk of malignancy.

Case Report

39-year-old male, with no significant history. Who comes to the general surgery outpatient clinic due to the presence of progressive abdominal distension and long-term abdominal pain without other accompanying symptoms. Physical examination showed no abnormal findings, except for mild abdominal discomfort on palpation. An abdominopelvic CT scan was performed, which revealed bilateral, well-circumscribed tumor with heterogeneous characteristics located in the left and right adrenal area; no venous thrombosis or metastatic lesion was observed. 24-hour urine cortisol and catecholamine accumulations were normal, as were serum aldosterone and ACTH levels. Subsequently, a bilateral biopsy was performed, reporting a left tumor in fragments of adipose tissue without evident atypia and a fibrolipoma on the

right. Based on the size of the tumor and persistence of symptoms, the surgical time is protocolized. An exploratory laparotomy was performed, revealing two giant adrenal tumors, the left measuring 30 x 15 cm and the right measuring 15 x 7 cm. Complete resection was performed without complications and the specimens were sent for definitive study, reporting bilateral adrenal leiomyoma. The patient progressed adequately and was discharged two days after his intervention.

Discussion

The adrenal glands are located in the retroperitoneum, above or medial to the upper renal poles. They have an approximate weight of 8-10 g [1]. These glands are endocrine organs in which two embryological origins are added: an ectodermal component (medulla) with secretion of catecholamines (norepinephrine and adrenaline) and a mesodermal component (cortex) in which the three lines of specialized corticosteroids are recognized.

In autopsy series, the prevalence of adrenal tumors varies between 1.4 and 8.7%. In studies carried out on a large number of patients scanned by computed tomography (CT), its prevalence is 0.6-1.9%, and even higher than 4% if patients with a previous diagnosis of neoplasia are included [2].

In any patient with a newly discovered adrenal tumor, it is equally important to determine whether the tumor is malignant and whether it is hormonally active to guide the best treatment. Malignancy is diagnosed in 5% to 8% of patients with adrenal tumors, with a

higher risk in young patients, if they have a history of extra-adrenal malignancy, in those with large adrenal tumors with indeterminate imaging features, and in bilateral adrenal tumors [3].

The etiology varies from benign to malignant tumors derived from the adrenal cortex, medulla or extra-adrenal origin; However, the vast majority are of adrenocortical origin, mostly adenomas. 69-75% of adrenal incidentalomas are non-functioning, 10-12% secrete cortisol, 7-10% pheochromocytomas, 2.5-6% aldosteronomas, 8-11% adrenal carcinomas and 5-7%. Metastasis [4].

Tumors of connective tissue origin are rarer and are mainly composed of hemangioma and lymphangioma with some cases of leiomyoma, lipoma, hemangiosarcoma, lymphoma, leiomyosarcoma and liposarcoma, as reported in the literature [5].

Adrenal leiomyoma is extremely rare and is believed to arise from the smooth muscle wall of the central adrenal vein and its branches. They occur in women and men to approximately the same extent and are located equally in the right and left adrenal glands [6].

Most patients present with abdominal or flank pain, and some with lower extremity edema, spider angiomas when the tumor invades the inferior vena cava [6].

These tumors generally have a low biological potential and affect both peripheral soft tissues and viscera, sometimes forming multiple independent tumors and often showing incomplete smooth muscle differentiation [7].

Leiomyoma does not produce adrenal hormones and there are no known tumor markers that are applicable for diagnosis [8].

The imaging findings of leiomyoma as a benign tumor are: well-defined margin and no signs of invasion of the surrounding parenchyma. Non-contrast computed tomography may reveal a hyperdense mass compared to healthy parenchyma. On contrast-enhanced computed tomography, leiomyoma may show less enhancement compared to the parenchymal environment with relatively homogeneous enhancement [9].

Histopathological and immunohistochemical evaluation helps determine the type of tumor and also helps in differential diagnosis [8].

In our case we present a bilateral adrenal tumor that was reported in histopathology as a leiomyoma, in the review of the literature it is described as extremely rare and more frequently associated with primary malignant neoplasms in the lung, breast, kidney, colon, esophagus, pancreas, liver., stomach or with melanoma can present adrenal metastases disseminated from these tumors and which can commonly be found bilaterally [10].

There are two main factors to consider when deciding whether an adrenal tumor should be removed surgically. The first is the functional status of the tumor and the second is the risk of malignancy [11].

Although the risk of malignancy clearly correlates with the size of a lesion, tumor size greater than 4 cm in diameter represents only 31 to 61% specificity for the diagnosis of malignant tumor. Therefore, the risk of malignancy and the decision on surgery should not be

based solely on the size of a tumor but rather evaluated in terms of imaging studies, growth pattern during follow-up, and a new tool that is steroid metabolites. in urine/serum [10].

Surgery in this patient was based on the CT findings that reported the large size of the adrenal mass. Furthermore, due to the size of the tumor, an excisional biopsy was necessary to rule out malignancy of the lesion.

Laparoscopic adrenalectomy is the standard of care for most adrenal tumors, although the procedure can be technically challenging for large masses, which is why an open approach was preferred in this case [12].

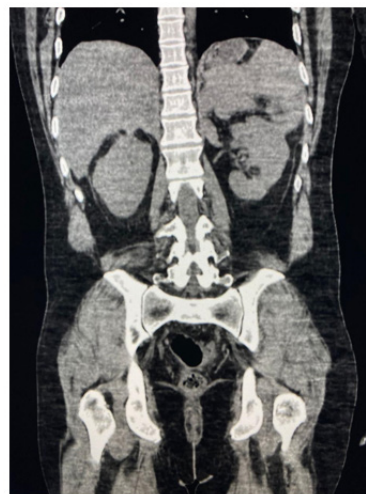

Figure 1: Computed Tomography of the Abdomen Showing Bilateral Adrenal Masses

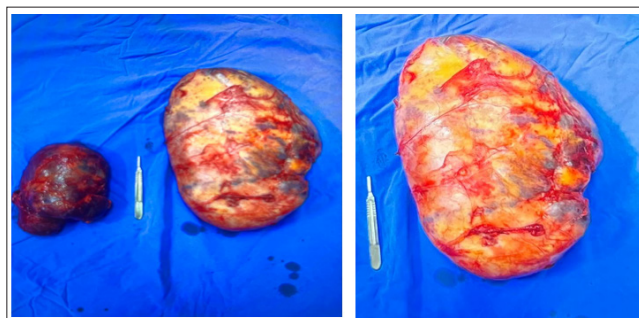


Figure 2: Gross Pathology Specimen Showing Bilateral Firm, lobulated, Well-Encapsulated Adrenal Tumor

Acknowledgements

“Thank you to all my colleagues, many of whom have become my friends, accomplices and brothers. Thank you for the hours shared, the work done together and the stories lived.”

Conclusion

In conclusion, the prevalence of adrenal tumors varies between 1.4 and 8.7%, we present a rare case of bilateral primary adrenal leiomyoma of which no similar case was found in the reviewed literature. These tumors are very difficult to diagnose preoperatively. as they are often not counted in adrenal samples and clinical suspicion is very low. As a result, they are diagnosed postoperatively after pathological examination of the surgical specimen. At the moment, early and complete surgical resection is the main treatment.

References

1. González-Albarrán O, Fraile J, García Robles R (2000) Fisiología de las glándulas suprarrenales. *Medicine* 81097-81101.
2. (2005) Tumoraciones suprarrenales: un hallazgo habitual en radiología abdominal. *Gastroenterol Hepatol Contin* 4: 244-247.
3. Bancos I, Prete A (2021) Approach to the Patient with Adrenal Incidentaloma. *J Clin Endocrinol Metab* 106: 3331-3353.
4. Corssmit EPM, Dekkers OM (2019) Screening in adrenal tumors. *Curr Opin Oncol* 31: 243-246.
5. Sakellariou M, Dellaportas D, Peppas M, Schizas D, Pikoulis E, et al. (2020) Review of the literature on leiomyoma and leiomyosarcoma of the adrenal gland: A systematic analysis of case reports 34: 2233-2248.
6. Zhou Y, Tang Y, Tang J, Deng F, Gong G, et al. (2015) Primary adrenal leiomyosarcoma: a case report and review of literature. *Int J Clin Exp Pathol* 8: 4258-4263.
7. Miettinen M (2014) Smooth muscle tumors of soft tissue and non-uterine viscera: biology and prognosis. *Mod Pathol* 27: S17-29.
8. Nerli RB, Ghagane S, Dixit NS, Hiremath MB, Deole S (2019) Adrenal leiomyosarcoma in a young adult male. *Int Cancer Conf J* 9: 14-17.
9. Pramod SV, Siregar S, Safriadi F, Hernowo BS, Firdaus GI (2020) The largest adrenal leiomyoma: A case report and literature review. *Urol Case Rep* 29 (101106): 101106.
10. Ambroziak U (2021) Approach to large adrenal tumors. *Curr Opin Endocrinol Diabetes Obes* 28: 271-276.
11. Pinto A, Barletta JA (2015) Adrenal tumors in adults. *Surg Pathol Clin* 8: 725-749.
12. Kumar S, Nanjappa B, Agrawal P, Pushkarna A (2014) Large bilateral adrenal leiomyomas presenting as calcified adrenal masses: a rare case report. *Korean J Urol* 55: 363-366.

Copyright: ©2024 María A Calderón González, et al. This is an open-access article distributed under the terms of the Creative Commons Attribution License, which permits unrestricted use, distribution, and reproduction in any medium, provided the original author and source are credited.