

## Case Report

## Open Access

# Hemangioma of Liver in a Patient with Neurofibromatosis Type I (Von Recklinghausen's Disease)

Madeeha Subhan Waleed <sup>1\*</sup>, Waleed Sadiq <sup>2</sup> and Sanniyah Subhan<sup>3</sup>

<sup>1</sup>Ayub Medical College, Pakistan, madeehas99@gmail.com

<sup>2</sup>Staten Island University Hospital, New York, waleedsadiq01@gmail.com

<sup>3</sup>Oakton Community College.

### SUMMARY

Neurofibromatosis (NF) is an inherited disorder of nervous tissue and skin and have two forms type 1 and type 2. We present to you a 62 year old male with neurofibromatosis having developed hemangioma in the left lobe of liver. NF1 patients should be managed in time to decrease morbidity and mortality of the patient.

### \*Corresponding author

Madeeha Subhan Waleed MBBS, Ayub Medical College, tel no:00923335634888, Pakistan. E-mail: madeehas99@gmail.com

**Received:** November 04, 2020; **Accepted:** November 09, 2020; **Published:** November 12, 2020

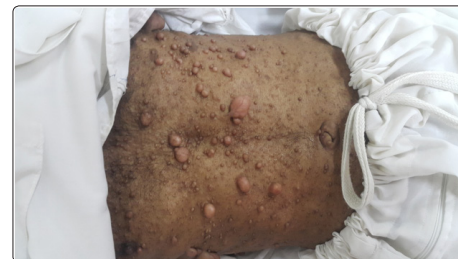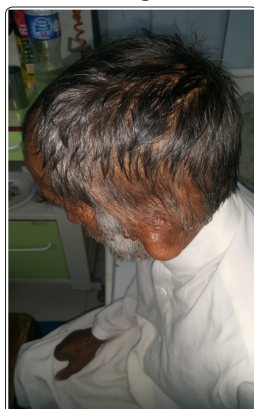**Keywords:** Neurofibromatosis; Hemangioma; Nervous; Von Recklinghausen's Disease; Benign.

### Introduction

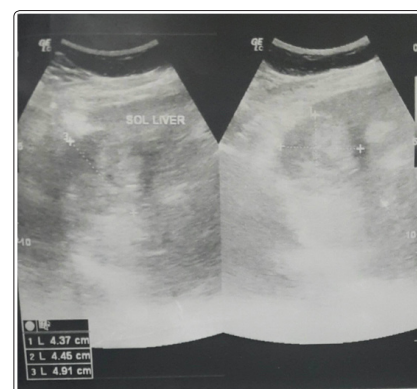
Neurofibromatosis (NF) is an inherited disorder of nervous tissue and skin and have two forms type 1 and type 2. [1-3]. NF1 accounts for 90 percent of all neurofibromatosis. This disease has a prevalence of 1/ 3,000 births [1-8]. Hepatic hemangiomas are benign malignancies that usually don't grow but if they grow they require intervention[9].

### Case Presentation

A 62 year old male presented to the hospital with abdominal pain and watery diarrhea since a week .he had 5 episodes in a day and the diarrhea was watery in consistency. He also complained of anorexia since the past month but no weight loss was documented. On examination he had dyspnea on exertion and his abdomen had guarding and was tender. His bowel sounds were positive. He smoked cigarette as well as hukka with a history of one pack per day for 25 years.No other comorbidities were present. He had pallor and neurofibromas all over his body with the largest being behind his left ear as shown in Figure: 1 and 2.



His rest of the systemic examination was normal. His ultrasound showed a hemangioma in the left lobe of the liver measuring 4.4cmX4.3X4.9cm as shown in Figure: 3



The patient was managed conservatively and recovered fine. Regular followup of the patient was done every 6 months to look for growth of hemangioma or any other complication related to NF1.

### Discussion

Neurofibromatosis type 1 also known as Von Recklinghausen's disease is a rare disease that is inherited tumors of nerves and skin. Friedrich Daniel von Recklinghausen wrote a paper in

the year 1882 on NF [10]. Robert William Smith explained the symptoms on NF in the year 1849 [11]. Von Recklinghausen's neurofibromatosis prevalence is between 1/3000 and 1/5000 live births [12]. Hemangioma is the most common type of benign tumor that occurs in the liver [13]. The prevalence of hemangioma is about 3%-20%. It is common in middle-aged women [14]. The patient has neurofibromatosis 1 having haemangioma in the left lobe of the liver.

### Conclusion

NF1 is a disorder involving almost the systems of the body and should be managed accordingly by a physician and a genetic specialist/geneticist. NF1 patients should be managed in time to decrease morbidity and mortality of the patient. More studies should be done in finding more treatment options for NF1. If diagnosed early the patients can be monitored to reduce the disabling complications that can happen.

There is no conflict of interest.

Informed Consent was taken from the patient.

### References

1. Gorlin RJ, Cohen MM, Levin LF (1990) Syndromes of the head and neck. Oxford: Oxford University Press 353-416.
2. Friedman JM, Gutmann DH, MacCollin M, Riccardi Y (1999) Phenotype, natural history and pathogenesis. Baltimore: The Johns Hopkins University Press; 1999. Neurofibromatosis.
3. Cunha KS, Barboza EP, Dias EP, Oliveira FM (2004) Neurofibromatosis type I with periodontal manifestation. A case report and literature review. Br Dent J 196: 457-60.
4. Bekisz O, Darimont F, Rompen EH (2000) Diffuse but unilateral gingival enlargement associated with von Recklinghausen neurofibromatosis: A case report. J Clin Periodontol 27: 361-365.
5. García-de Marcos JA, Dean-Ferrer A, Alamillos-Granados F, Ruiz-Masera JJ, García-de Marcos MJ, et al. (2007) Gingival neurofibroma in a neurofibromatosis type 1 patient. Med Oral Patol Oral Cir Bucal 12: 287-291.
6. Hillier JC, Moskovic E (2005) The soft tissue manifestations of neurofibromatosis type 1. Clin Radiol 60: 960-7. [PubMed]
7. Bongiorno MR, Pistone G, Aricò M (2006) Manifestations of the tongue in Neurofibromatosis type 1. Oral Dis 12: 125-129. [PubMed]
8. Cotran RS, Kumar V, Robbins SL (2010) Robbins pathologic basis of disease. 8th ed. Philadelphia: Saunders Company; 2010.
9. J A Mungovan, J J Cronan, J Vacarro (1994) "Hepatic cavernous hemangiomas: lack of enlargement over time" Radiology 191: 111-113.
10. Paine RS (1956) A clinical, pathological and genetic study of multiple neurofibromatosis. American Journal of Human Genetics 8: 190.
11. Kobrin JL, Blodi FC, Weingeist TA (1979) Ocular and orbital manifestations of neurofibromatosis. Surv Ophthalmol 24: 45-51.
12. Boyd KP, Korf BR, Theos A (2009) Neurofibromatosis type 1. Journal of the American Academy of Dermatology 61: 1-4.
13. Ishak KG, Rabin L (1975) Benign tumors of the liver. Med Clin North Am 59: 995-1013. [PubMed]
14. Choi BY, Nguyen MH (2005) The diagnosis and management of benign hepatic tumors. J Clin Gastroenterol 39: 401-412.

**Copyright:** ©2020 Madeeha Subhan Waleed. Wilfried. This is an open-access article distributed under the terms of the Creative Commons Attribution License, which permits unrestricted use, distribution, and reproduction in any medium, provided the original author and source are credited.