

**Research Article**
**Open Access**

## Mucor Mycosis Maiming COVID-19 Recovered Patients in India?

**K Suresh**

Public Health Consultant Bengaluru and Visiting Professor- MPH. KSRDPRU Gadag, Karnataka, India

**ABSTRACT**

The year 2021 will go in the history of Indian Ophthalmology as the year of fungal infections among Covid 19 recovered patients as a leading cause of vision or eye loss and facial disfigurement due to post -Covid 19 Fungi- mucor mycosis infections. First published article of mucor mycosis (MM) leading to loss of eye and disfigurement of the face was traced to 1970 in USA. First media report in India came from Ganga Ram Hospital in Delhi, that treated 12 cases of COVID triggered deadly Mucor mycosis fungus cases. Eye & ENT surgeon had to do resection and fungus debridement in 10 cases in one fortnight in December 2020 of which half lost one eye permanently. Mucor mycosis (MM) is an aggressive opportunistic fungal infection, affecting any parts of the body, but rhino-cerebral-orbital type is the commonest leading to blindness and facial disfiguration. Doctors at Bowring and Lady Curzon Medical College Hospital, Bengaluru which has treated more than 140 patients with mucor mycosis, after cell culture tests have confirmed in 95% of the cases the presence of Mucor mycosis, and remaining MM, Aspergillus niger and Candida albicans. Since Mid-April 2021 India has reported about 31,000 MM cases as on 12 June 2021. It is feared that nearly 50% of them have lost at least one eye and some both. Five states of Maharashtra, Gujarat, Rajasthan, Karnataka, and Andhra Pradesh contribute nearly two thirds of the cases and deaths. The latest report of 1700 hrs on 13 June 2021, from Maharashtra puts the total cases at 7395, deaths at 720, 2212 cured and 4463 still under treatment. This state has seen threefold increase in the MM cases reported in just 3 weeks' time between 25th May and 13 June 2021. Among those recovered one has witnessed lot of facial disfigurement, due to the damages to eyes, nose, jaw bones and oral cavity. Some of them who can afford go in for multiple plastic surgeries costing anywhere between INR 2.5 to 15 million. Traditionally mucor mycosis treatment must start without waiting for laboratory confirmation, but recently a new diagnostic tool with the capability for confirming infection in 24-48 hours is being promoted and is likely to help minimise the damage at least among those who can afford. In this review I have collated and presenting epidemiology, Pathophysiology, available diagnostic support, and treatment of MM infections affecting eyes, nose and disfigurement of face and possible reconstructive surgeries from various sources.

**\*Corresponding author**

Suresh Kishanrao, Public Health Consultant Bengaluru and Visiting Professor- MPH. KSRDPRU Gadag, Karnataka, India. Tel No: 919810631222.  
E-mail: Ksuresh.20@gmail.com

**Received:** June 10, 2021; **Accepted:** June 18, 2021; **Published:** June 30, 2021

**Keywords:** Mucor Mycosis, Aggressive Fungi, COVID-19 Orbital Manifestation, Amphotericin B Injection, Surgical Debridement

**Introduction**

Eye contact is often important when communicating with others, conditions that involve the eye are not only important for physiological functioning of vision but also for an individual's facial figure. Any change or damage to an individual's eyes often disfigure her/his face. Removing an eye is one of the most noticeably disfiguring conditions. Prostheses are remarkably good these days but cannot match a real eye and people are disproportionately affected by seeing people who are missing an eye [1]. Thousands of people develop or are born with a squint. Numerous eye conditions can create a visible difference-like, one eye being smaller or larger than normal, Ptosis- where the eyelid droops, removal of an eye due to cancer, an infection or other condition.

Loss of vision, complete (involving both eyes) or partial, involving only one eye or even certain parts of the visual field, is different from blindness that was present at birth. Vision loss can also be considered as loss of sight that cannot be corrected to a normal level with eyeglasses. It can occur suddenly or develop gradually over

time. The causes of vision loss in an individual who had normal vision, range from conditions affecting the eyes to conditions and the visual processing centres in the brain. Common causes of vision loss in the elderly include diabetic retinopathy, glaucoma, age-related macular degeneration, and cataracts.

The general causes of loss of vision listed in literature include Bacterial Infection, CMV Retinitis, Corneal Scars, Eye Tumour, Ischemic Optic neuropathy, Medications, Onchocerciasis, Stargate's Disease, Toxins/Poisoning, Trauma, Viral Infections of the Eye and Vitamin A Deficiency [2]. American and GOI guidelines for management of mucor mycosis infections in Covid 19 patients recommend surgical debridement of fungal growth sans laboratory confirmation [3-5]. The year 2021 will go in the history of Ophthalmology in India as the year of post-Covid 19 Fungi- mucor mycosis contributing sizeably for disfigurement of the face and vision loss among Indians [6].

A PubMed search took me to first published article of 1970, that described 11 cases of mucor mycosis seen in an institution in USA since 1970. Of nine patients with underlying diabetes mellitus, 8 had developed rhino cerebral mucor mycosis and one had the cutaneous form. The diagnosis was established by

histologic appearance and by culture of infected tissue obtained by biopsy [7]. Ganga Ram Hospital in Delhi, India saw 12 cases of COVID triggered deadly Mucor mycosis fungus in a post Covid 19 recovery stage. Eye & ENT surgeon had to do resection and fungus debridement in 10 cases in one fortnight in December 2020 of which half lost one eye permanently [8].

Mucor mycosis is an aggressive opportunistic fungal infection, affecting any parts of the body such as the lungs and gastrointestinal tract, the Brain but the rhino-cerebral-orbital type is the commonest. It is caused by organisms of the family Mucoraceae. The spores of the fungus are inhaled through the mouth and nose, but infection occurs an immunocompromised individual as s/he is unable to mount an effective immune response against the inhaled spores; thus, germination and hyphae formation occur and infection develops, most commonly in the sinuses and lungs. When the fungus invades the paranasal sinus mucosa, it may spread directly to the orbital apex and, from there, gain intracerebral access.

Mucor mycosis is difficult to diagnose early, as patients often present with nonspecific symptoms. By the time signs of orbital apex involvement develop, it is often too late to save the patient's vision, or even the patient's eye or life. Facial deformity is the most talked about symptom of the disease. Mucor mycosis can prove to be quite dangerous if untreated, as it mutilates a patient's nose, jaw, or alter the vital facial structure. The formation of black crusts, swelling in and around the nasal passage and the eyes is a peculiar feature. The disease rapidly spreads from nose and sinuses to the eye and brain in a span of 24 to 48 hours, if not diagnosed in early stage or the treatment not initiated on time, almost 50% of patients lose one sided a few bilateral eyesight. In many severe cases, surgeries maybe even required to remove jawbone, Nose, or the nose. Once it involves the brain, the mortality is approximately 80% [4].

India has seen about 31,000 MM cases as on 12 June 2021. It is feared that nearly 50% of them have lost at least one eye and some both. Five states of Maharashtra, Gujarat, Rajasthan, Karnataka, and Andhra Pradesh contribute nearly two thirds of the cases and deaths. The latest report of 1700 hrs on 13 June 2021, from Maharashtra puts the total cases at 7395, deaths at 720, 2212 cured and 4463 still under treatment. This state has seen threefold increase in the MM cases reported in just 3 weeks' time between 25th May and 13 June 2021. Among those recovered many press reports indicate lot of facial disfigurement, due to the damages to eyes, nose, jaw bones and oral cavity. Some of them who can afford go in for multiple plastic surgeries costing anywhere between INR 2.5 to 15 million. 30,000 cases the beginning of the second phase of Covid 19 Pandemic since late April 2021. There are more than 1,700 people suffering mucor mycosis cases in Karnataka as of 7 June 2021 of which 62 have recovered [3,5-9].

### Materials Methods

Reports of MM infections from Ministry of Health & Family Welfare, GOI, State National Health Mission media briefing, online Published articles, and Press reports in national and Provincial newspapers like Times of India, Indian Express, Hindu, Live Mint, Aljazeera and NDTV.

### Epidemiology

The disease has a predilection for individuals with diabetes mellitus, patients with severe neutropenia with organ transplants or hematopoietic malignancies; or those on chronic steroids or

immunosuppressants treatment as in late cancers and recently Covid 19 severe and moderate cases and multiple blood transfusions [4].

### Pathogenesis

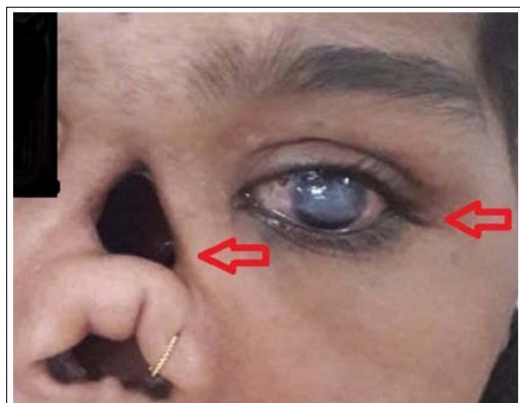In Diabetic or immunocompromised patients, the organisms invade the paranasal sinus mucosa; they may remain contained there or progress into the orbit or brain parenchyma. The fungal hyphae may directly invade blood vessels, producing tissue infarction and massive necrosis with bone destruction. The Ethmoid sinus is an important route of infection. From here, the organisms may extend posteriorly to the orbital apex, leading to orbital apex syndrome. The optic nerve may be affected, resulting in vision loss. Involvement of the superior orbital fissure and its contents, such as cranial nerves III, IV, and VI, and branches of V1 and V2, may cause diplopia, ophthalmoplegia, and sensory loss to the corresponding areas of the cornea and face. With further posterior extension, the fungus may gain access to the cavernous sinus and to the brain parenchyma, causing vascular thrombosis and infarction. Being aggressively invasive, progression of the infection is very rapid [4].

### Rhino-Orbito-Cerebral Mucor Mycosis (ROCM)

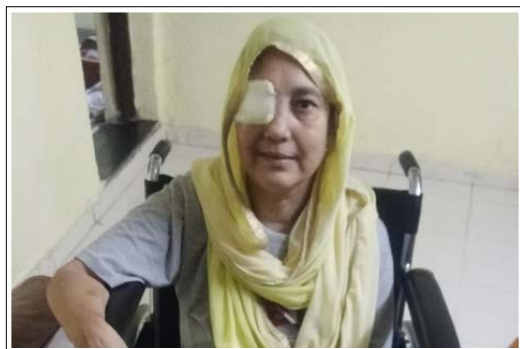This disease originates from the nose and rapidly spreads along the sinus passage to infect the orbit (bone cavity which surrounds the eye) and brain. Hence, the infection can be classified into three stages. In the initial stage, when the patient will experience either nasal blockage or congestion, nasal discharge -bloody or brown/ black and localized pain inside the nose. The patient will then start to develop facial pain, numbness or even swelling of the face. As the infection progresses and reaches the orbit, the patient begins to experience headache and orbital pain- in or behind the eye. Blurred or double vision with pain, vision loss in one or both eyes, resulting in partial or complete blindness [4].

The onset of sinus mucor mycosis starts with nonspecific symptoms such as nasal congestion, postnasal drip, dark blood-tinged or purulent rhinorrhoea, sinus tenderness, headache, fever, and malaise. As the infection progresses, symptoms like facial or periorbital swelling or numbness, blurred vision, chemosis, proptosis, diplopia, ophthalmoplegia, corneal anaesthesia, and loss of vision, due to invasion of the orbital nerves and vessels. Neurological changes like, hemiparesis, or seizures suggests intracranial invasion. The time from the onset of initial symptoms to signs that are diagnostic of the disease may be as short as 24-48 hours, indicating a poor prognosis [4].

Ophthalmic manifestations may be the presenting feature of COVID-19 infection, or they may develop several weeks after recovery due to mucor mycosis infections. Direct effect due to virus, immune mediated tissue damage, activation of the coagulation cascade and prothrombotic state induced by the viral infection, the associated comorbidities and drugs used in the management of Covid 19 moderate to severe infections are responsible for the findings in the eye. Conjunctival congestion, lid oedema, hyperaemia, watering, Follicular conjunctivitis, Conjunctival chemosis, epiphora, hyperaemia, secretions, Dryness, relapsing viral keratoconjunctivitis and Episcleritis are the symptoms and signs. The viral ribonucleic acid (RNA) has been isolated from ocular tissues but the role of eye as a route for infection is not substantiated [4].



Rhino-ocular MM infection resistant to Amphotericin B, disfiguring the face



MM infection of left eye (Top) at an early stage & Late stage- right eye removed (bottom)

### Diagnosics

Mucor mycosis being an invasive disease, early diagnosis is of great importance. The gold standard diagnosis for the infection is to isolate and test for the fungus through cell culture studies. As it takes 10 to 15 days, and the infection spreads fast, leading to loss of vision and even life clinching diagnosis cannot wait and therefore the test is not much useful [3]. 'KOH microscopy test' is another that is widely used and yields swift results. It picks up infection by detecting fungal filaments but may not pick up infections if the fungi load is less. It does not differentiate between different types of fungi. It is cheapest test available, but accuracy is an issue. Very Recently Molecular Diagnostic Laboratory (MDL) of Narayana Nethralaya Bengaluru, India has validated a Dutch RT-PCR kit to diagnose mucor mycosis, that can deliver results in 24 to 48 hours. Called 'MucorGenius', this test detects genetic material or the nuclei code of the fungi and helps in early. detection and save patients eyesight and lives.

The test costs Rs 7,000 (US \$100). The test works even if the fungal load is less claimed the director of MDL. The test can detect five species of mucor families called 'pan mucorace'. Blood and tissue from the biopsy are considered biomarkers for the test. This test will help in successful management of patients with an appropriate anti-fungal treatment and avoid morbidity and mortality. MucorGenius has received CE-IVD (European Community In-Vitro Diagnostic device) certification. About 15 samples have been tested in the lab. In Bengaluru and the lab has started receiving samples from private hospitals [11].

### Magnitude of the Problem

India as of early June 2021 has reported over 31,000 black fungus cases and about 2100 deaths approximately and the number is increasing every day. Mucor mycosis cases have been reported from 28 states and UTs. Out of them 86% of infections had a history of Covid-19 and 62.3% a history of diabetes. Five states of Maharashtra, Gujarat, Rajasthan, Karnataka, and Andhra Pradesh contribute nearly two thirds of the cases and deaths. The latest report of 1700 hrs on 13 June 2021, from Maharashtra puts the total cases at 7395, deaths at 720, 2212 cured and 4463 still under treatment. This state has seen threefold increase in the MM cases reported in just 3 weeks' time between 25th May and 13 June 2021. The case fatality rate due to MM (in addition to Covid 19 CFR of 1-2%) we consider as dead taking CFR to 6.8% [3].

### Discussions

The first ever multicentric retrospective was conducted across India to compare epidemiology and outcomes among cases of coronavirus disease (COVID-19)-associated mucor mycosis (CAM) during September-December 2020. Among 287 mucor mycosis patients, 187 (65.2%) had CAM; CAM prevalence was 0.27% among hospitalized COVID-19 patients. A 2.1-fold rise in Mucor mycosis was observed during the study period (231) as compared with September-December 2019 (112). Uncontrolled diabetes mellitus was the most common underlying disease among CAM and non-CAM patients.

COVID-19 was the only underlying disease in 32.6% of CAM patients. COVID-19-related hypoxemia and glucocorticoid use were independently associated with CAM. The Mucor mycosis case-fatality rate at 12 weeks was 45.7% but was similar for CAM and non-CAM patients. Age, rhino-orbital-cerebral involvement, irrational use of corticosteroids and intensive care unit admission were associated with increased mortality rates. Sequential antifungal drug treatment improved mucor mycosis survival.

The COVID-19 pandemic has led to increase in fungal infections, partly from inappropriate glucocorticoid use and poor monitoring of blood sugar and its management after going home. Consequent loss of vision, removal of eye as part of debridement surgery led to disfigurement of face among about 15,000 persons in the last 2 months.

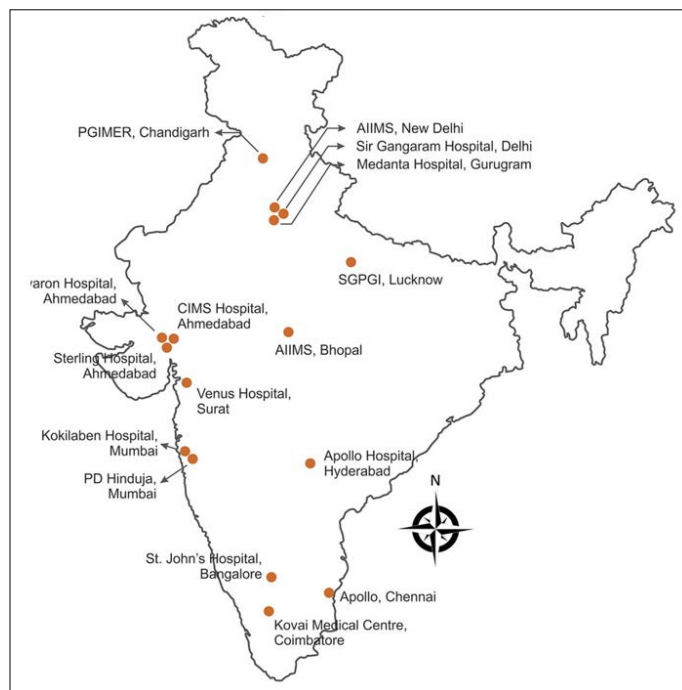
Secondary infections are known to complicate the clinical course of coronavirus disease (COVID-19). Bacterial infections are the most common secondary infections but increasing reports of systemic fungal infections are causing concern. In the early part of the COVID-19 pandemic, <1% of secondary infections reported in COVID-19 patients were fungal [1,2]. Pre-existing conditions, indiscriminate use of antimicrobial and glucocorticoid drugs, and lapses in infection control practices are putative factors contributing to the emergence of systemic fungal infections in severe COVID-19 cases (4). One study reported invasive fungal infections in ≈6% of hospitalized COVID-19 patients (7).

## BALCK FUNGUS DEVASTATING COST & DISFIGUREMENT

In February 2021, Paul, a railway employee was operated upon, and an eye was removed. He was treated by 13 surgical efforts and all in all spent INR 1.5 Crore. The operation had left a hollow in his face and eye. While eating, the food would enter the hole where he used to have his eye. The problem was eventually solved with a prosthetic. He is happy that his life was saved.

Nilesh a security guard in his late thirties from Yavatmal in Maharashtra, a Covid 19 recovered person's first one eye was removed and 10 days later, the other one too. The family has spent Rs 20 lakh, part of which was funded by selling the house but now has become dependent on his wife and needs occupational rehabilitation.

Akola's Ajay and Subodh were both operated for removal of facial bones and then plastic surgeries done. Little can be known about the jaw bones that were removed now



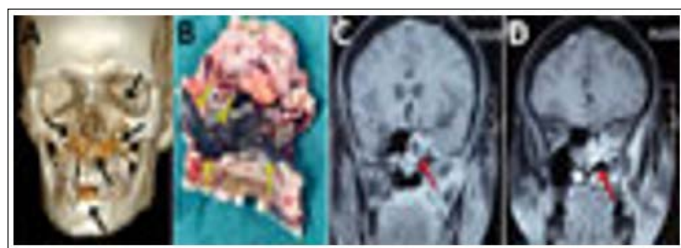
Radiographic images and surgical specimens demonstrating rhino-orbital-cerebral coronavirus disease-associated mucor mycosis in patients from India, 2020.

A) Three-dimensional reconstruction of computed tomography scan of 54-year-old male patient. Black arrows indicate patchy osteonecrosis involving the upper jaw, right orbital wall, and paranasal sinuses.

B) Surgical specimen from the maxilla of 54-year-old male patient showing black necrotic paranasal sinus with palatal involvement indicated by yellow arrows.

C, D) Magnetic resonance imaging (MRI) of coronal section of paranasal sinus and brain of 51-year-old female patient. Red arrow in panel C indicates enhancing cavernous sinus lesion.

D) red arrow in panel D indicates right ethmoid and maxillary sinusitis. Scale bar indicates 7 cm.



**Figure 3:** Radiographic images and surgical specimens demonstrating rhino-orbital-cerebral coronavirus disease-associated Mucor mycosis in patients from India, 2020.

A) Three-dimensional reconstruction of computed tomography scan of 54-year-old male patient. Black arrows indicate patchy...

### Conclusion

India is only the country reporting large numbers of fungal infections leading to disfigurement of the face following recovery from Covid 19 hospitalized patients. Not all fungal infections in patients were due to mucor mycosis, *Aspergillus Niger*, and *Candida albicans* are among other fungi that are infecting patients. Lack of early diagnostic tools has led to delay in antifungal treatment, increased need for surgical debridement and removal of the eyes, nose, sinuses etc. disfiguring the face. The cost and shortage of antifungal injections (Amphotericin B) is another

The number of Mucor mycosis cases unrelated to COVID-19 did not differ much during both the study periods (112 cases in 2019 vs. 92 cases in 2020), indicating the increase in 2020 was chiefly attributed to CAM. A greater percentage of patients with CAM had hypoxemia requiring ICU admission during hospitalization than the non-CAM group. The rhino-orbital region was the most common mucor mycosis site (58.2%), followed by rhino-orbital-cerebral, pulmonary, and other sites. However, site of involvement was similar in both the CAM and the non-CAM groups. Toothache, loosening of teeth, and radiologic involvement of the jaw were noted in many CAM patients but were not seen in non-CAM patients. Only one participating centre reported jaw involvement in 10/47 (21.3%) contributed CAM cases. The common form of pulmonary involvement was cavitary lung disease.

contributor for the misery. As plastic surgery is costly not many people can afford and must live with disfigured face.

### Way Forward

Popularise the new diagnostic test of Ducth RTPCR test MucorGenius for early diagnosis

Make available Amphotericin B injections free of cost in the public sector. Promote surgical interventions in tertiary/teaching hospitals through PPP mode if needed.

### References

1. What causes facial disfigurement? <http://www.lets-face-it.org.uk>.
2. Melissa Conrad Stöppler, Vision Loss <https://www.medicinenet.com>.
3. (2021) Mucor mycosis Cases Grow.
4. Courtney Y Kauh, Christing c Nelson, Sharon Fekrat, Ingrid u scott (2014) Diagnosis and Management of Orbital Mucor mycosis, American Academy of Ophthalmology, <https://www.aao.org/eye>.
5. Guideline for management of Mucor mycosis in Covid 19 patients, <https://www.dghs.gov.in>.
6. Mrittika Sen, Santosh G Honavar, Namrata Sharma, Mahipal S Sachdev (2021) COVID-19 and Eye: A Review of Ophthalmic Manifestations of COVID-19, Indian. J Ophthalmol 69: 488-509.
7. R Rangel-Guerra, H R Martínez, C Sáenz (1985) Mucor mycosis- Report of 11 cases. Arch Neurol 42: 578-581.
8. Atul Patel, Ritesh Agarwal, Shivaprakash M. Rudramurthy, Manoj Shevkani, et al.(2021) early release Multicentre Epidemiologic Study of Coronavirus Disease–Associated Mucor mycosis, India. <https://wwwnc.cdc.gov/eid/article/27/9/21>.
9. Joymala Bagchi (2020) deadly mucor mycosis cases in Covid 19 recovered patients worries doctors, <https://www.aninews.in>.
10. Mucor mycosis, Maharashtra-Gujarat-among-worst-hit-states- <https://www.livemint.com>.
11. Black-fungus-new scare in-India as-second-covid 19 waves, <https://www.aljazeera.com>.
12. Sunitha Rao, Bengaluru lab's RT-PCR kit detects mucor in 48 hrs, <https://epaper.timesgroup.com/Bengaluru> edition 9 June2021.

**Copyright:** ©2021 Suresh Kishanrao. This is an open-access article distributed under the terms of the Creative Commons Attribution License, which permits unrestricted use, distribution, and reproduction in any medium, provided the original author and source are credited.