

Research Article

Open Access

Study of Corneal Curvature with Pterygium Morphology in Tertiary Care Center in Central India

Shishir Garg¹, Shubhangi Dubey², Priyanka^{3*} and Ulka Srivastava⁴

¹Junior resident, Department of Ophthalmology, Chirayu Medical College and Hospital, Bhopal, India

²Senior resident, Department of Ophthalmology, Chirayu Medical College and Hospital, Bhopal, India

³Assistant Professor, Department of Ophthalmology, Chirayu Medical College and Hospital, Bhopal, India

⁴Professor & HOD, Department of Ophthalmology Chirayu Medical College and Hospital, Bhopal, India

ABSTRACT

Purpose: To evaluate the correlation between corneal astigmatism and pterygium morphology by anterior segment optical coherence tomography.

Methods: Patients diagnosed with unilateral pterygium were included in this prospective cross-sectional study. A thorough history was taken and each patient underwent detailed ocular examination including demographic data, subjective refraction with best corrected visual acuity using a Snellen's chart, anterior and posterior segment examination with slit lamp biomicroscopy, keratometric measurements using an autorefractometer. The vertical width and horizontal length of the pterygium was measured manually with the millimetric scale of the slit lamp biomicroscope.

Results: The study consisted of 45 patients with a mean age of 54.58 years. Mean Horizontal pterygium length, vertical width and percentage extension of pterygium was 2.71 mm, 4.56 mm, 50.22% respectively. Mean anterior corneal astigmatism was 2.11 ± 1.69 . Analysing the correlation separately, a statistically significant correlation was present between horizontal length and percentage extension and the anterior corneal astigmatism.

Conclusion: Anterior corneal astigmatism was higher in pterygium group as compared to the contralateral eye without pterygium.

*Corresponding author

Priyanka, Assistant Professor, Department of Ophthalmology Chirayu medical college and hospital, Bhopal, India.

Received: March 29, 2023; **Accepted:** March 31, 2023; **Published:** April 07, 2023

Keywords: Pterygium, Astigmatism, Anterior Segment Optic Coherence Tomography

Introduction

Pterygium is a degenerative disorder of the fibrovascular subconjunctival connective tissue that spreads as wing-shaped growth to enter the cornea, damaging the Bowman's membrane and superficial layers of stroma [1]. Pterygium causes corneal distortion and induces significant amount of astigmatism. This astigmatism may occur either due to traction generated by the pterygium, pulling on and distorting the cornea, or by tears pooling near apex of the pterygium or both. Due to the limited flattening of the region between the central cornea and the advancing end of the pterygium, it frequently causes corneal astigmatism with the rule [2].

Prevalence of pterygium has been estimated to range from 1.1-23.4% [4]. Various previous studies have examined the impact of various pterygium diameters on corneal refractive status as determined by refraction, keratometry, and corneal topography. These investigations showed greater associations between

pterygium diameters and corneal astigmatism [3,4].

Few histological and clinical research have been done on the morphological patterns of pterygium. Anatomical information about the ocular surface is available from Anterior Segment Optic Coherence Tomography (AS-OCT) [figure 1,2], which can be utilised to study the interaction between the pterygium and the cornea [5]. A thick hyperreflective layer between the corneal epithelium and Bowman's layer in pterygium was identified in a study using AS-OCT.

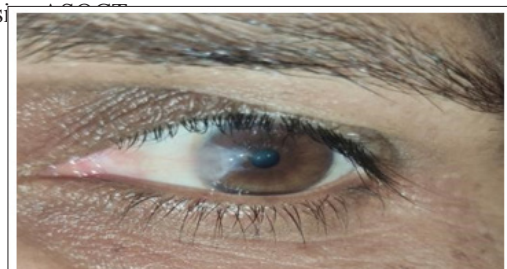

Figure 1: Anterior Segment Photograph of Pterygium

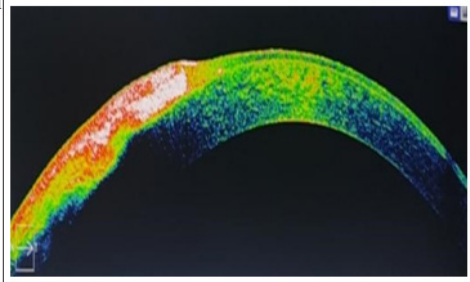


Figure 2: Anterior Segment Optical Coherence Tomography

Few studies have been done in India using AS-OCT to study the relationship between pterygium morphology and corneal astigmatism. In this study, AS-OCT was used to assess the effects of pterygium size and morphology on corneal astigmatism.

Material and Methods

This prospective cross-sectional study was conducted at a tertiary eye care centre of central India included 45 primary pterygium patients. Eyes with recurring pterygium, a history of ocular surgery or trauma, corneal scarring, or any irregularity that would have affected the corneal morphology were excluded from study. The Institutional Review committee gave its approval for this study (Refno:CMCH/IEC/2022/84 ,28/10/2022), which was carried out in accordance with the Declaration of Helsinki. Informed and written consent was taken from each participant.

All subjects underwent a thorough ocular examination that included demographic information, subjective refraction, best-corrected visual acuity using a Snellen chart, examining the anterior and posterior segments examination with slit-lamp microscopy, keratometric measurements using autorefractometer and analysing pterygium morphology.

One examiner manually measured the pterygium’s vertical width and horizontal length (in millimetres) using a millimetric scale of the biomicroscope. The distance between the apex of the pterygium and the nasal limbus is measured as the horizontal length (C), and the vertical breadth is measured along the line connecting the two limbal sites (L) where the pterygium contacts the limbus. We acquired high-resolution anterior segment images using AS OCT by same examiner. The AS- OCT’s images enable the examiner to precisely assess how the pterygium and cornea are related anatomically. Photographs were assessed individually and all images were subjected to the same analysis by two independent observers who were blinded to the clinical data of the subjects. Horizontal OCT scans at the limbus, the centre of the cornea, and the tissue’s apex were taken. Scans with insufficient illumination or misaligned scans were excluded.

Pterygium images show a thick, hyperreflective subepithelial lesion between the Bowman layer and the corneal epithelium that is covered by normal epithelium that exhibits varying degrees of hyperreflectivity. The extent of the pterygium apex below the corneal epithelium was used to evaluate the pterygium’s morphology.

Statistical analyses were performed using Microsoft Excel software. Mean, Standard Deviation (SD) and Range was observed for every parameter. Evaluations of the horizontal length, vertical width, percentage extension (%), and values for corneal astigmatism were done using Spearman correlation analysis. Results were

considered statistically significant if the p value was less than 0.05.

Results

The study included 45 patients out of which 23 were males and 22 were females, with a mean age of 54.58 ± 9.54 (31-65) years. The average best corrected visual acuity was 0.34 ± 0.22 . The mean vertical breadth 4.56 ± 1.38 ranged from 2 to 6.5 mm and the mean horizontal pterygium length ranged from 1.5 to 3.75 mm with a mean of 2.71 ± 0.69 mm. The pterygium’s percentage extension was $50.22 \pm 17.89\%$. Mean anterior corneal astigmatism was 2.1 ± 1.69 D (0.25–7.25). [Table 1]

Table 1: Showing Demographic, Clinical and Topographic Parameters of Patients

	Mean	S.D.	Range
Age(years)	54.58	9.54	31-65
BCVA	0.34	0.22	0.1-1
Horizontal length(mm)	2.71	0.69	1.5-3.75
Vertical length(mm)	4.56	1.38	2-6.5
Pterygium extension (%)	50.22	17.89	18.81-93
Corneal astigmatism (D)	2.1	1.69	0.25-7.25

BCVA, Best Corrected Visual Acuity; SD, Standard Deviation

The relationship between pterygium diameters and anterior corneal astigmatism was analysed using Spearman correlation analysis. Pterygium horizontal length ($p < 0.001$, $r = 0.244$), vertical breadth ($p < 0.001$, $r = 0.218$), percentage extension of the pterygium ($p < 0.001$, $r = 0.207$) and pterygium area ($p < 0.001$) all showed positive moderate linear correlations with anterior corneal astigmatism [figure 3,4,5]. Among these, the association between percentage extension and the horizontal length of the pterygium is the most significant

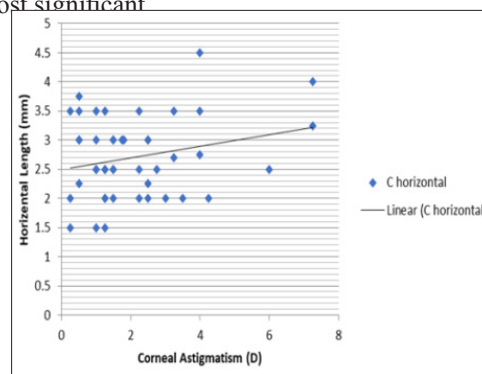


Figure 3: Correlation analysis between corneal astigmatism and horizontal length

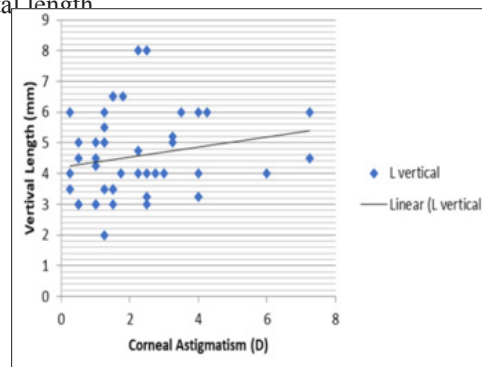


Figure 4: Correlation analysis between corneal astigmatism and vertical length

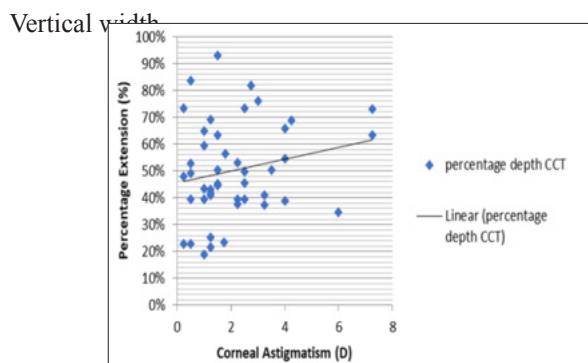


Figure 5: Correlation analysis between corneal astigmatism and pterygium extension

Discussion

The findings of our study showed that whereas larger pterygia are associated with higher anterior corneal astigmatism, their shape did not significantly affect astigmatism. The majority of research investigations in the literature have main focus on topography and visual changes brought on by pterygium.

Toktam et al. reported that astigmatism and high-order corneal aberrations can both be caused by pterygia, and the severity of each is inversely linked to the size of the pterygium [3]. The width, length, and total area of the pterygium have all been found to significantly correlate with the corneal refractive status in various studies. Similar to our findings, previous studies have shown that larger pterygium diameters are connected to pterygium-induced corneal astigmatism [6]. According to previous research by [7], pterygium area (extension width) and pterygium extension (distance from limbus to apex) had a stronger impact on corneal astigmatism than width (measured at the limbus). Refraction, automated keratometry, and slit-lamp analysis were used to ascertain this [7]. We found similar observations in our study where pterygium extension into the cornea more linked with corneal astigmatism as compared to horizontal or vertical length of pterygium. As per Lin and Stern study pterygium exceeding >45% of the radius induces significant amount of astigmatism showing significant correlation between pterygium size and corneal astigmatism [8]. Our findings were also consistent with this study [9], reported that astigmatism, asymmetry, and irregularity of the cornea were found to be negatively impacted by larger pterygia, as measured by the percentage extension of pterygium on the cornea [9]. According, when the length of the pterygium exceeds 2.25 mm, there was astigmatism of 2.00D or more. Similar findings were found in research conducted by numerous other authors [10]. We found similar results in our study. Pterygium larger than 3mm caused 1.97D of astigmatism, whereas those smaller than 3mm caused 1.11D, according to Hansen et al [11]. Similarly we found in our study that length of pterygium more than 3 mm results in more than 2.00 D corneal astigmatism. According to a study by Avisar et al, when a primary pterygium reaches past the limbus by more than 1 mm, it causes substantial WTR astigmatism >1.0D, which increased as the pterygium size increases [12].

Reported that the evaluation of different morphometric parameters, ASOCT is a helpful tool that aids in the monitoring of pterygium and the surgical planning associated with it [2].

A change in pterygium length is visible in the BCVA. More refractive astigmatism is caused by increased pterygium

limbal width. Astigmatism measured horizontally on AS-OCT is significantly correlated with keratometric astigmatism. On ASOCT, a number of pterygium parameters, such as epithelial thickness, pterygium head thickness, limbal thickness, and length of pterygium, demonstrate an impact on both keratometric and refractive astigmatism that is otherwise impossible to distinguish from slit lamp examination [5].

The AS-OCT parameters of pterygium that could be related to clinical observations were reported by [13]. AS-OCT is a crucial diagnostic technique that enables in vivo histological evaluations of the anterior segment and offers precise pictures of the ocular surface, particularly the cornea [5].

Limitations of our study was small number of subjects. Even though measurements were made by the same examiner repeatedly under the same circumstances, it's possible that they weren't objectively accurate when they were done manually. With larger patient groups, more precise results can be obtained. In addition to the morphological examination, measurements of the pterygium's invasion depth at the limbus or apex could be made to provide more details. The link between pterygium and the cornea with AS-OCT needs to be studied with bigger sample sizes.

Conclusion

In conclusion, the findings of the present study showed that larger pterygium sizes are related to greater anterior corneal astigmatism. There is a strong connection between the size of the pterygium and the refractive change caused by the pterygium leading to visual impairment and astigmatism. It can be useful to use AS-OCT to assess the pterygium's shape and provide appropriate information. In order to evaluate the relationship between pterygium and the cornea with AS-OCT, studies with larger sample sizes are required.

Financial Support and Sponsorship

The authors received no financial support for the research, authorship, and/or publication of this article.

Conflict of Interest

The authors declared that they have no potential conflict of interest.

References

1. Akriti Gumber, Prateek Nishant, Sony Sinha, Richa Goel, KPS Malik (2021) Changes in corneal curvature and visual acuity in North Indian adults after pterygium excision with modified suture less, glue less limbal-conjunctival autograft Indian journal of ophthalmology 69: 2401-2405.
2. Anuradha Raj, Renu Dhasmana, Harsh Bahadur (2021) Morphometric evaluation and measurements of primary pterygium by anterior segment optical coherence tomography and its relation with astigmatism. Ther Adv Ophthalmol 13: 1-11.
3. Toktam Shahraki, Amir Arabi, Sepehr Feizi (2021) Pterygium: an update on pathophysiology, clinical features and management. Ther Adv Ophthalmol 13: 1-21.
4. Emine Dogan, Burcin Cakir, Nilgun Aksoy, Elif Kose, Gursoy Alagoz (2021) Does pterygium morphology affect corneal astigmatism? Ther Adv Ophthalmol 13: 1-8.
5. Soliman W, Mohammad TA (2012) Spherical domain anterior segment optical coherence tomography assessment of pterygium and pinguecula. Acta Ophthalmol 90: 461-465.
6. Bhardwaj Veena, Das Alka Priyadarshini, Bhardwaj Gaurav (2013) Pterygium – A study which was done in a rural based population. Journal of clinical and diagnostic research 7:

- 1936-1937.
7. Payman AK Mohammad-Salih, Ahmad Fauzi Sharif (2008) Analysis of pterygium size and induced corneal astigmatism. *Cornea* 27: 434-438.
8. Lin A, Stern G (1998) Correlation between pterygium size and induced corneal astigmatism. *Cornea* 17: 28-30.
9. Tomidokoro A, Miyata K, Sakaguchi Y, Samejima T, Tokunaga T, et al. (2000) Effects of pterygium on corneal spherical power and astigmatism. *Ophthalmology* 107: 1568-1571.
10. Kampitak K (2003) The effect of pterygium on corneal astigmatism. *J Med Assoc Thai* 86: 16-23.
11. Hansen A, Norn M (1980) Astigmatism and surface phenomenon in pterygium. *Acta Ophthalmol* 58: 174-181.
12. Avisar R, Loya N, Yassur Y, Weinberger D (2000) Pterygium induced corneal astigmatism. *Isr Med Assoc* 2: 14-15.
13. Gasser T, Romano V, Serifarh C (2017) Morphometric characterisation of pterygium associated with corneal stromal scarring using high resolution anterior segment optical coherence tomography. *Br J Ophthalmol* 101: 660-664.

Copyright: ©2023 Priyanka, et al. This is an open-access article distributed under the terms of the Creative Commons Attribution License, which permits unrestricted use, distribution, and reproduction in any medium, provided the original author and source are credited.