

## Research Article

## Open Access

## Ocular Findings on Patients after Anti-PD-1/PD-L1 Antibodies Treatment: A Prospective Observation Report, A Pilot Study

Maho Sato<sup>\*</sup>, Hirohisa Kubono<sup>1</sup>, Kazuya Yamashita<sup>1</sup>, Takashi Nagamoto<sup>1</sup>, Yoshiko Ofuji<sup>1</sup>, Ryuki Fukumoto<sup>1</sup>, Hideko Akagi<sup>2</sup>, Mari Kawamura<sup>1</sup> and Kotaro Suzuki<sup>1</sup>

<sup>1</sup>Department of Ophthalmology, Keiyu Hospital, Kanagawa, Japan

<sup>2</sup>Department of Internal Medicine, Keiyu Hospital, Kanagawa, Japan

### ABSTRACT

**Purpose:** Immune Checkpoint Inhibitors (ICIs) cause ICI-related adverse events (irAEs) such as dry eye and uveitis, which can be severe, sometimes necessitating the suspension of ICI treatment. Retrospective studies have targeted ocular irAEs which can detect only moderate to severe symptomatic uveitis. To the best of our knowledge, this is the first prospective study on ocular irAEs. We aimed to investigate symptomatic and subclinical ocular changes in ICI-treated eyes, to identify early changes in ocular irAE and control conditions without suspending ICI treatment.

**Methods:** 22 participants who began ICI treatment between July 2020 and July 2021 in Keiyu Hospital, Japan (3 women and 19 men; age,  $69.1 \pm 7.9$  years, range, 53–83 years) were prospectively evaluated. The patients underwent ocular examinations before and 1, 3, and every 2 months after the initial dose of ICI. Examinations included measurement of best-corrected visual acuity, fundus biomicroscopy, spectral domain Optical Coherence Tomography (OCT) and aqueous flare. Central choroidal thickness (CCT) was measured using OCT.

**Results:** Among the 22 participants, 6 developed systemic irAEs. Of these 6 patients, one experienced ocular pain after ICI treatment, likely due to dry eye disease. We did not observe any change in CCT or aqueous flare, even in patients with systemic AEs. We were unable to ascertain whether CCT or aqueous flare are valuable clues for the early identification of ocular irAEs. We continue this prospective study with a larger sample size.

**Conclusions:** Systemic irAEs are not necessarily accompanied by ophthalmological changes.

### \*Corresponding author

Maho Sato MD, Department of Ophthalmology, Keiyu Hospital 3-7-3 Minatomirai, Nishiku, Yokohama, Kanagawa, Japan, Tel: +81-45-221-8181.

**Received:** March 17, 2024; **Accepted:** March 19, 2024; **Published:** March 28, 2024

**Keywords:** Immune Checkpoint Inhibitor (ICI), Immune-Related Adverse Event (irAE), Aqueous Flare, Central Choroidal Thickness (CCT)

### Introduction

Immune Checkpoint Inhibitors (ICIs) are immunologic agents that prevent the growth of cancer cells by blocking inhibitory receptors, such as programmed death 1 (PD-1) and programmed death protein ligand 1 (PD-L1) [1,2]. Ocular side effects secondary to ICIs are rare and reportedly occur in < 1% of patients, with dry eye and uveitis being the most frequent [1,3]. The characteristics of ocular side effects have gradually been recognized, and some cases of uveitis after ICI use resemble Vogt-Koyanagi-Harada disease (VKH) [4-7]. We have previously reported a case where a patient, after nivolumab treatment, developed annual choroidal detachment after getting intravitreal injection of anti-VEGF. Some cases have severe visual disturbance so that ICI treatment have to be halted. However, the frequency, timing of onset, and clinical characteristics have yet to be determined.

In previous reports about the prevalence of ocular immune checkpoint inhibitor-related adverse events (irAEs), ophthalmologic

examinations were performed only when patients had ophthalmic complaints. Therefore, there is a possibility that only symptomatic changes were recognized as irAEs.

As ICIs might be the only treatment left for some patients, it is ideal that irAEs can be predicted, identified early, and well controlled. This prospective study aimed to determine the clinical patterns of ocular irAEs, including slight and subclinical ocular changes, so that patients can continue cancer treatment without suspending ICI treatment.

### Materials and Methods

#### Patients

Recruited patients were those who began ICI treatment between July 2020 and July 2021 at Keiyu Hospital, Japan. The patients were referred to the ophthalmology department by their physician. The study protocol adhered to the tenets of the Declaration of Helsinki and was approved by the Keiyu Hospital Institutional Ethics Committee (approval number R2-57). Written informed consent was obtained from every patient.

## Eye Examinations

A total of 29 participants were recruited for this study. All patients underwent ocular examinations, including measurement of best-corrected visual acuity (BCVA) using a Landolt C chart, intraocular pressure (non-contact tonometer), fundus biomicroscopy, fundus photography, and spectral domain optical coherence tomography (OCT; Swept Source OCT, Triton, Topcon, Japan). OCT angiography and anterior segment OCT were done as well as fundus OCT.

Central Choroidal Thickness (CCT) was defined as the distance between the retinal pigment epithelium and the choroid-sclera boundary and was measured using the built-in scale of the OCT system. All measurements were recorded with reference to the scale bars in the OCT system. In the previous reports, CCT increases in VKH-like uveitis eyes as inflammation occurs in choroid [7].

Aqueous flare was measured using an FM-600 laser flare meter (Kowa Co., Osaka, Japan). Seven consecutive flare readings with a background scatter of < 15% were acquired and averaged after excluding the minimum and maximum measurements. The results are presented as photon counts per millisecond (pc/ms). Increase in aqueous flare indicates inflammation in the anterior chamber.

Before ICI treatment, fundus biomicroscopy, fundus photography, OCT, and flare meters were performed with dilated pupils with tropicamide 0.5% and phenylephrine 0.5%. All recruited patients underwent systemic ophthalmologic examinations 1, 3, and every 2 months after the beginning of ICI treatment. Considering the physical condition of each patient, ophthalmologic examinations were performed with non-dilated pupils after the treatment began, if there was no subjective or objective change.

## Statistical Analysis

Patient anonymity was maintained throughout the data collection and statistical analysis.

All data are expressed as the mean  $\pm$  standard deviation. A comparative analysis between participants was performed using a paired t-test. Statistical significance was set at  $P < 0.05$ . The paired t-test was performed using Prism for Windows, version 9.1.0 (GraphPad Software, Inc., USA).

## Results

### Patients and Clinical/Ophthalmologic Characteristics

Of the 29 participants, 7 were excluded as they died before examination one month after the beginning of the treatment because of primary disease. This prospective study included 44 eyes of 22 participants (3 women and 19 men; mean age  $69.1 \pm 7.9$  years; range, 53-83 years) (Table 1). They were followed up for more than one month after the beginning of ICI treatment.

Among the 22 patients, 11 were followed up for 3 months after the initial treatment, 7 for 5 months, and 6 for 7 months. The study included 5 patients with a history of cataract surgery more than one year previously. None of the patients had a history of uveitis.

**Table 1: Patients' Characteristics**

Age	69.1 $\pm$ 7.9(53-83)	
Sex (male[%])	19[86.3]	
	right eye	left eye
AL (mm)	24.4 $\pm$ 1.1	24.4 $\pm$ 1.1
SE (diopter)	-1.6 $\pm$ 2.5	-1.9 $\pm$ 2.9
IOP (mmHg)	13.7 $\pm$ 3.2	13.7 $\pm$ 2.4
CRT ( $\mu$ m)	216.2 $\pm$ 30.6	222.9 $\pm$ 36.4

Data are expressed as the mean  $\pm$  standard deviation.

The primary cancers were located in the lungs (n=8, 36.3%), stomach (n=8, 36.3%), esophagus (n=2, 9.1%), kidney (n=2, 9.1%), pancreas (n=1, 4.5%), and bladder (n=1, 4.5%). ICIs included nivolumab (n=15, 68.2%, with 2 patients also treated with ipilimumab), durvalumab (n=3, 13.6%), pembrolizumab (n=2, 9.1%), and atezolizumab (n=2, 9.1%) (Table 2). The interval between each treatment was 2 weeks for nivolumab and durvalumab, and 3 weeks for pembrolizumab and atezolizumab.

**Table 2: Immune Checkpoint Inhibitors Used**

ICI	Number of patients
Nivolumab	13
Nivolumab+Ipilimumab	2
Pembrolizumab	2
Durvalumab	3
Atezolizumab	2
total	22

Number of patients for each ICI treatment is indicated.

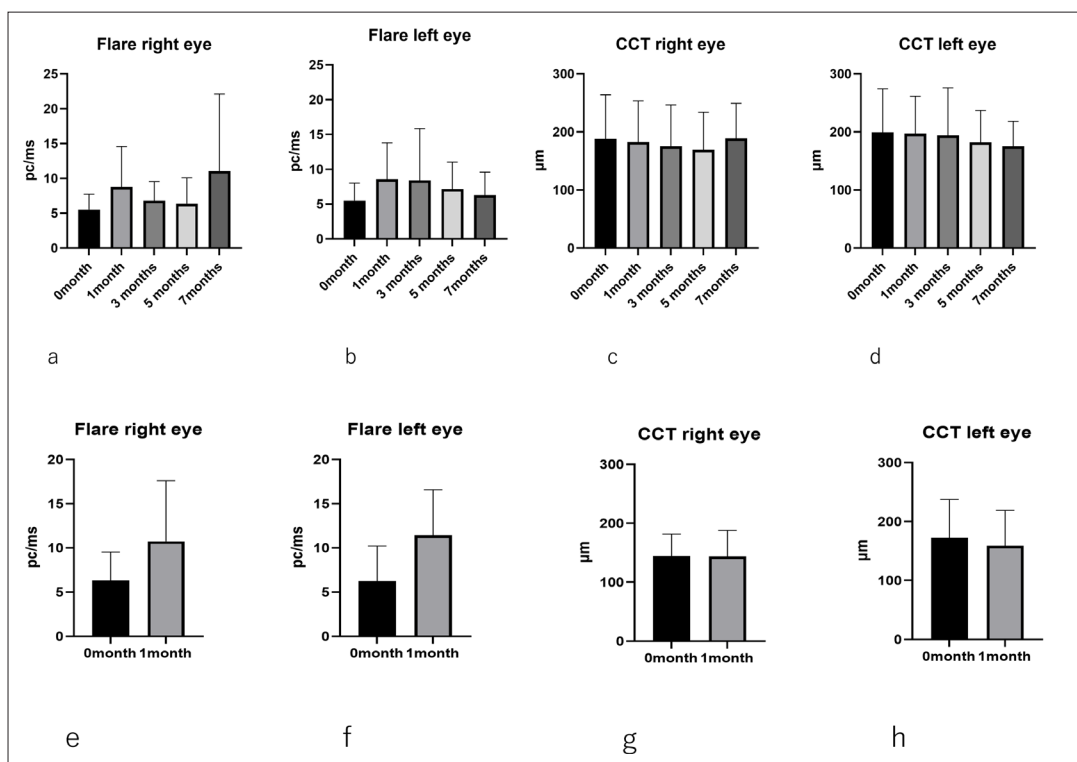
The ophthalmic characteristics of the participants at the baseline are presented in Table 1. For the right and left eye, the respective mean axial length was  $24.4 \pm 1.1$  mm and  $24.4 \pm 1.1$  mm, mean spherical equivalent was  $-1.6 \pm 2.5$  and  $-1.9 \pm 2.9$ , and mean intraocular pressure was  $13.7 \pm 3.2$  mmHg and  $13.7 \pm 2.4$  mmHg (Table 1).

The baseline CCT value for the right and left eye was  $188.0 \pm 74.4$   $\mu$ m and  $199.5 \pm 75.0$  respectively (Table 3). Respective aqueous flare values were  $5.5 \pm 2.2$  pc/ms and  $5.5 \pm 2.5$  pc/ms (Table 3).

**Table 3: Comparisons of Ocular Findings Between Baseline and Different Time Points**

	base line n=22		1 month n=22				3months n=11				5months n=7				7months n=6			
	right eye	left eye	right eye	p-value	left eye	p-value	right eye	p-value	left eye	p-value	right eye	p-value	left eye	p-value	right eye	p-value	left eye	p-value
CCT (µm)	188.0 ± 74.4	199.5 ± 75.0	186.9 ± 0.8	0.99	195.8 ± 0.8	0.99	175.4 ± 67.8	0.99	194.1 ± 77.7	0.99	169.3 ± 60.1	0.97	182.0 ± 50.8	0.98	189.2 ± 54.9	>0.999	175.3 ± 39.2	0.94
flare (pc/ms)	5.5 ± 2.2	5.5 ± 2.5	8.9 ± 5.6	0.06	8.7 ± 5.1	0.08	6.8 ± 2.6	0.97	8.42 ± 7.1	0.51	6.4 ± 3.4	0.99	7.2 ± 3.6	0.93	11.1 ± 11.1	0.15	6.3 ± 3.0	0.99

Data are expressed as the mean ± standard deviation; Paired t-test. CCT, central choroidal thickness



**Figure 1: Paired-Samples T-Test of 22 Participants**

- a. Differences in aqueous flare between baseline and 1, 3, 5, and 7 months after initiation of treatment (right eye).
- b. Differences in aqueous flare between baseline and 1, 3, 5, and 7 months after initiation of treatment (left eye).
- c. Differences in CCT between baseline and 1, 3, 5, and 7 months after initiation of treatment (right eye).
- d. Differences in CCT between baseline and 1, 3, 5, and 7 months after initiation of treatment (left eye).
- e. Differences in aqueous flare between baseline and 1, 3, 5, and 7 months after initiation of treatment (right eye).
- f. Differences in aqueous flare between baseline and 1, 3, 5, and 7 months after initiation of treatment (left eye).
- g. Differences in CCT between baseline and 1, 3, 5, and 7 months after initiation of treatment (right eye).
- h. Differences in CCT between baseline and 1, 3, 5, and 7 months after initiation of treatment (left eye).

Throughout the observation period, no participant reported visual disturbance. The mean aqueous flare and CCT showed no significant differences before and after the treatment (Table 3, Figure 1).

**Systemic irAEs**

Six patients (#1 to #6) experienced systemic irAE. Patient #1 developed interstitial pneumonia after eight treatments with nivolumab and ipilimumab. ICI treatment was suspended and oral prednisolone was initiated. The patient complained of ocular pain in both eyes a few days after each treatment, which persisted even after oral prednisolone was initiated. The patient was diagnosed with dry eye disease prior to ICI treatment. The tear break-up time was 4 s in both eyes before and after ICI treatment, with slight superficial punctate keratopathy. There were no other objective changes in the ocular findings.

Patient #2 developed adrenocorticotropic hormone deficiency 3 months after the last dose of atezolizumab for stomach cancer. Atezolizumab was discontinued after three doses to evaluate progressive disease. Oral prednisolone was administered to the patient.

Patient #3 developed hypothyroidism and pituitary adrenal dysfunction after the second dose of nivolumab and ipilimumab for lung cancer. ICI was discontinued, and oral corticosteroids were started. Oral prednisolone was administered to the patient.

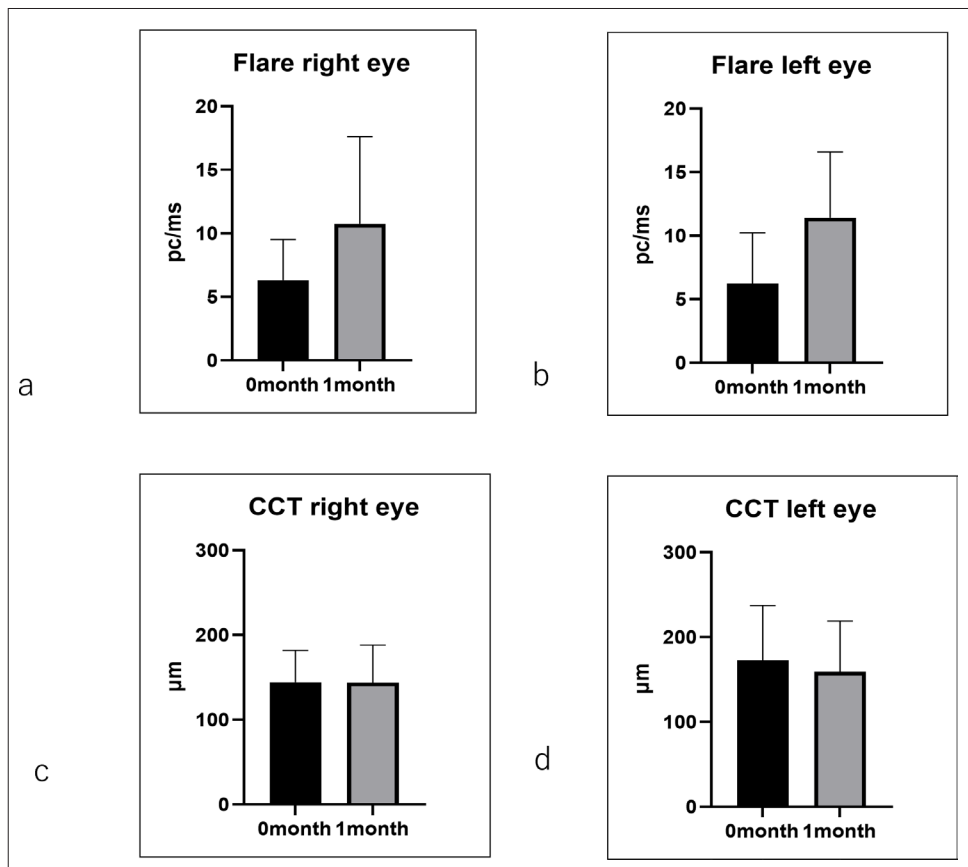
Patient #4 developed hypothyroidism after eight treatments with durvalumab. Levothyroxine was initiated, and durvalumab was continued. Ocular inflammation was not observed.

Patient #5 developed hypothyroidism, interstitial pneumonia, and sensory neuropathy after the third treatment with durvalumab.

Oral prednisolone was administered to the patient. As lung cancer was judged as a progressive disease, durvalumab treatment was not continued. Ocular inflammation was not observed.

Patients #6 developed hypothyroidism after the first treatment with nivolumab. As the performance status deteriorated, nivolumab was discontinued. Ocular inflammation was not observed.

These six patients did not show significant changes in CCT and aqueous flare (Figure 2 a-d).



**Figure 2:** Paired-Samples T-Test of 6 Participants with Systemic irAEs  
a. Differences in flare between baseline and one month after treatment (right eye).  
b. Differences in flares between baseline and one month after treatment (left eye).  
c. Differences in CCT between baseline and one month after treatment (right eye).  
d. Differences in CCT between baseline and one month after treatment (left eye).

## Discussion

By targeting patients with and without ocular symptoms, we aimed to identify subclinical ocular changes and clinical features of ocular irAEs. The prevalence of ocular irAE anti-PD-(L)1 treatment is reportedly < 1%, most frequently manifesting as uveitis (1%) and dry eye (1–24%) [1,2]. As most of the reported PD-1 inhibitor-related ocular complications occur within a few weeks to months after infusion, we performed a year follow-up [2].

None of the patients had visual impairments. One patient reported ocular pain after the ICI treatment. Patient #1 (Table 4) had dryness in both eyes before ICI treatment with a tear break-up time (BUT) of 4 seconds in both eyes with slight superficial punctate keratopathy. The symptoms were worse for 2 weeks after every ICI treatment. The patient visited our clinic one week after the second ICI treatment, complaining of ocular pain in both eyes. But was also 4 second in both eyes with slight keratopathy at that time. We cannot conclude that the cause of ocular pain was deterioration of dry eye. However, the ICI treatment might have been influential in causing ocular pain. Including this patient as having dry eye as an ocular irAE, our result is consistent with the statistics (n=1, 3.7%) [2].

**Table 4: Demographics, Drug Regimen, and Cancer Type of 6 Patients with Systemic irAEs**

patient	age	gender	ICI regimen	cancer diagnosis	systemic irAE	onset of systemic irAE	ocular irAE
#1	73	male	Nivolumab Ipilimumab	lung cancer	interstitial pneumonia	after 8 <sup>th</sup> treatment	dry eye
#2	77	male	Atezolizumab	stomach cancer	ACTH deficiency	3 months after third(last) treatment	none
#3	62	male	Nivolumab Ipilimumab	lung cancer	hypothyroidism/pituitary adrenal dysfunction	after second treatment	none
#4	74	male	Durvalumab	lung cancer	hypothyroidism/pituitary	after 8 <sup>th</sup> treatment	none
#5	62	male	Durvalumab	lung cancer	hypothyroidism/pituitary interstitial pneumonia sensory neuropathy	after the third treatment	none
#6	66	female	Nivolumab	pancreas	hypothyroidism/pituitary	after the initial treatment	none

No patient showed inflammatory change in both anterior or posterior segment. Exudative changes or retinal pigment epithelium rippling was not observed. We expected that choroidal thickness might increase in some patients after ICI treatment, as seen in VKH. However, the CCT did not show a significant change in our study.

Six participants experienced systemic irAEs. One of the patients (#1) complained of ocular pain. The other patients did not have ocular symptoms. Both CCT and aqueous flare did not show any significant differences before and after treatment in these six cases (Figure 2).

In normal eyes, PD-L1 is detected in corneal epithelial cells, corneal endothelial cells, iris/ciliary body cells, and retinal pigment epithelial cells [8]. PD-L1 expressed on human ocular cells is thought to play a role in controlling ocular inflammation by inhibiting the production of proinflammatory and Th2 cytokines by activated T cells [8]. There is a possibility that ICI might collapse the immune control system at the blood-ocular barrier and increase the aqueous flare. This was not observed in this study (Table 3 and Figure 1). However, several factors are related to aqueous flare measurements. Application of mydriatic agent, pupil size, and diurnal variation of aqueous flares might have affected the test results. Aqueous flare intensity reportedly decreased significantly 1 h after the application of a mydriatic agent [9-11]. In the present study, we measured the flare intensity 30 min after the application of tropicamide 0.5% and phenylephrine 0.5%, which may have decreased the flare intensity. We did not dilate the pupil from the second visit, as the patients were undergoing chemotherapy and were not willing to undergo dilation. We understood the discomfort of having dilated pupils. Considering that the baseline was measured with a dilated pupil that decreases aqueous flare and that there were no significant differences in aqueous flare between the baseline and after ICI treatment, we can suggest that aqueous flare did not increase after ICI treatment.

Most of the reported PD-1 inhibitor-related ocular complications occurred within a few weeks to months after infusion, while there was no change in the ophthalmological findings in our observation [2].

The present study has several limitations. One is the small sample size. Inclusion of various types of cancer and ICIs is another. In addition, the follow up period is short because of

the enrolled patients were all cancer patients, some of whom died, which shortened the follow-up period. The timing of the ophthalmologic test after ICI treatment was one month after the treatment. However, this timing could have missed ocular changes that occurred just after the treatment.

We tested the participants without mydriasis after ICI treatment, considering the patients' conditions. However, matching the condition was needed to evaluate the differences in aqueous flare before and after ICI treatment.

As our participants did not develop ocular inflammation, we do not know whether choroidal thickness or aqueous flare might change in patients with ocular irAEs. Here, we described a one-year follow-up of the patients after ICI treatment. We are continuing this prospective study to validate the results of the present study using a larger sample size.

#### Declaration

##### Ethics Approval and Consent to Participate

The study protocol adhered to the tenets of the Declaration of Helsinki and was approved by the Keiyu Hospital Institutional Ethics Committee (approval number R2-57). Written informed consent was obtained from every patient participating in this study.

##### Consent for Publication

Not applicable.

##### Availability of Data and Materials

The datasets used and analyzed during the current study are available from the corresponding author on reasonable request.

##### Competing Interests

The authors declare that they have no competing interests.

##### Funding

Not applicable.

##### References

1. Antoun J, Titah C, Cochereau I (2016) Ocular and orbital side-effects of checkpoint inhibitors: A review article. *Curr Opin Oncol* 28: 288-294.
2. Dalvin LA, Shields CL, Orloff M, Sato T, Shields JA (2018) CHECKPOINT INHIBITOR IMMUNE THERAPY: Systemic Indications and Ophthalmic Side Effects. *Retina* (Philadelphia, Pa.) 38: 1063-1078.

3. Abdel Rahman O, Oweira H, Petrusch U, Helbling D, Schmidt J, et al. (2017) Immune-related ocular toxicities in solid tumor patients treated with immune checkpoint inhibitors: a systematic review. *Expert Rev Anticancer Ther* 17: 387-394.
4. Obata S, Saishin Y, Teramura K, Ohji M (2019) Vogt-Koyanagi-Harada Disease-Like Uveitis during Nivolumab (Anti-PD-1 Antibody) Treatment for Metastatic Cutaneous Malignant Melanoma. *Case Rep. Ophthalmol* 10: 67-74.
5. Matsuo T, Yamasaki O (2017) Vogt-Koyanagi-Harada disease-like posterior uveitis in the course of nivolumab (anti-PD-1 antibody), interposed by vemurafenib (BRAF inhibitor), for metastatic cutaneous malignant melanoma. *Clin. Case Rep* 5: 694-700.
6. Telfah M, Whittaker TJC, Doolittle G (2019) Vision loss with pembrolizumab treatment: A report of two cases. *J. Oncol. Pharm. Pract* 25: 1540-1546.
7. Bricout M, Petre A, Amini Adle M, Bezza W, Seve P, et al. (2017) Vogt-Koyanagi-Harada-like Syndrome Complicating Pembrolizumab Treatment for Metastatic Melanoma. *J. Immunother. Cancer* 40: 77-82.
8. Yang W, Li H, Chen PW, Alizadeh H, He Y, et al. (2009) PD-L1 expression on human ocular cells and its possible role in regulating immune-mediated ocular inflammation. *IOVS* 50: 273-280.
9. Oshika T, Kato S (1989) Changes in aqueous flare and cells after mydriasis. *Jpn. J. Ophthalmol* 33: 271-278.
10. El Harazi SM, Ruiz RS, Feldman RM, Chuang AZ, Villanueva G (2002) Quantitative assessment of aqueous flare: the effect of age and pupillary dilation. *Ophthalmic Surg. Lasers Imaging Retina* 33: 379-382.
11. Oshika T, Araie M, Masuda K (1988) Diurnal variation of aqueous flare in normal human eyes measured with laser flare-cell meter. *Jpn J. Ophthalmol* 32: 143-150.

**Copyright:** ©2024 Maho Sato, et al. This is an open-access article distributed under the terms of the Creative Commons Attribution License, which permits unrestricted use, distribution, and reproduction in any medium, provided the original author and source are credited.