

Case Report

Open Access

Longitudinal Monitoring of Normal Tension Glaucoma: A Case Report

Lena HY Li¹, Victor CP Woo² and George C Woo^{3*}¹School of Optometry, The Hong Kong Polytechnic University, Hong Kong²Hong Kong Ophthalmic Associates, Hong Kong³School of Optometry, The Hong Kong Polytechnic University and Centre for Eye and Vision Research, Hong Kong**ABSTRACT**

Normal Tension Glaucoma (NTG) is a sub-type of primary open angle glaucoma (POAG) with Intraocular Pressure (IOP) lower than or equal to 21mmHg. It is diagnosed when optic disc cupping, visual field testing and Optical Coherence Tomography (OCT) show corresponding findings of progressive optic neuropathy. Once NTG is diagnosed, treatment focusing on lowering the IOP is usually given to slow down the NTG progression. However, the progression can sometimes be so slow that no medical or surgical interventions are required. A 55-year-old Chinese woman was diagnosed to have NTG, but she only has had occasional follow-ups at an ophthalmology centre with no treatment initiated. Very slow progression has been observed in both eyes over 17 years. This case report demonstrates the natural history of NTG and shows that medication and/or surgery are sometimes not necessary.

***Corresponding author**

George C Woo, School of Optometry, The Hong Kong Polytechnic University and Centre for Eye and Vision Research, Hong Kong.

Received: August 26, 2024; **Accepted:** August 28, 2024; **Published:** September 09, 2024**Keywords:** Normal Tension Glaucoma, Vision-Related Quality of Life, Collaborative Eye Care**Introduction**

Normal Tension Glaucoma (NTG) is a type of Primary Open-Angle Glaucoma (POAG) in which intraocular pressure (IOP) is lower than or equal to 21mmHg [1]. The pathogenesis of NTG is multifactorial. Although IOP in NTG patients is normal, it has been found that IOP is one of the key factors leading to the development and progression of NTG, and that lowering IOP can retard the glaucomatous damage in NTG effectively [2,3]. There are also IOP-independent factors including reduced ocular perfusion pressure, vascular dysregulation, blood vessel endothelium dysfunction, mechanical force on lamina cribosa, myopia, and genetics. In addition, there are systemic risk factors such as obstructive sleep apnoea, migraine, and hypotension which may increase the risk of having NTG [4]. Recently, it has been found that resistance exercise, high cognitive efforts and stress and playing wind instruments may be correlated to the incidence of glaucoma due to the increase in IOP [5-7].

NTG is diagnosed by meeting the following criteria [8-10]

- IOP lower than or equal to 21mmHg
- Open anterior chamber angles
- Damage in optic discs with glaucomatous cupping and neuroretinal rim loss
- Retinal nerve fibre bundle defects detected in fundus photo and Optical Coherence Tomography (OCT) which are usually localized, close and inferior to fovea [11]
- Ganglion cell layer thinning detected in OCT
- Reduction in microcirculation of optic nerve detected in OCT angiography

- Visual field defects matching glaucomatous damage present in optic nerve head
- No secondary causes of glaucoma or other causes of optic neuropathy
- Progression of glaucomatous damage detected.

Fundus exams, OCT and visual field can observe the progression of the glaucomatous damage. Increased optic disc cupping or the presence of disc haemorrhage may indicate progression [12]. Retinal nerve fibre layer (RNFL) thinning can be defined as age-related when it is from -0.21 to -0.44 $\mu\text{m}/\text{year}$, slow when slower than -1 $\mu\text{m}/\text{year}$; moderate when between -1 μm and -2 μm ; and fast if greater than -2 μm [13-16]. The age-related decrease in sensitivity in the visual field is -0.043dB/ year before 53.4 years old, and the rate increases to -0.102dB/ year after 53.4 years old [17]. The rate is slow when it is slower than -0.5dB/year, moderate when in between -0.5 to -1dB/year, and fast when greater than -1dB/year [13,18,19].

Lowering IOP has been found to be effective in slowing down the progression of NTG. This can be achieved by instilling IOP-lowering eyedrops, laser trabeculoplasty, trabeculectomy, or Minimally Invasive Glaucoma Surgery (MIGS). However, if the normal tension glaucoma is not treated, it usually progresses slowly or, in other cases, does not progress at all. In the Collaborative Normal-Tension Glaucoma Study (CNTGS), 65% of the subjects did not progress without treatment. Han et al. also found that only 10.3% and 24.8% of the untreated NTG subjects showed progression in visual field in three years and five years respectively [20]. This case report demonstrates the natural history of untreated NTG over 17 years, and shows that very slow progression is possible in NTG patients even without treatment.

Case report

First Visit

A 55-year-old Chinese female presented herself to the School of Optometry Clinic of the Hong Kong Polytechnic University for an eye examination in 2005. She had undergone Laser Assisted in Situ Keratomileusis (LASIK) in both eyes in 1998 and her pre-operation refraction was OD -3.00/-0.25x105; OS -2.75/-0.75x125. She reported to be healthy, not on any medication, and had no known drug allergy. Her unaided distance Visual Acuity (VA) was 6/6 for OD and OS. Her pupil reflexes were normal in both eyes. Retinoscopy results were OD +0.75 and OS +0.75/-0.50x10. Subjective refraction results were OD +0.75 (6/6) and OS +0.75/-0.50x15 (6/6). In the ocular health examination, mild nuclear sclerosis was present in both eyes. She was also found to have superior and inferior RNFL defects in OD, and inferior RNFL defects in OS. Cup-to-Disc (C/D) ratios were 0.6 in both

eyes. IOP measured by Non-Contact Tonometry (NCT) with computerized tonometer CT. 80 (Topcon) was OD 14mmHg and OS 13mmHg. Central Corneal Thickness (CCT) measured by Orbscan I (Orbtek, Inc.) was OD 541 μm and OS 542 μm. RNFL OCT performed by Stratus OCT model 3000 (Carl Zeiss, Meditec Inc.) revealed superior and inferior RNFL thinning in OD and inferior RNFL thinning in OS, as shown in Table 3. Automated perimetry with central 30-2 SITA standard threshold visual field testing was performed with the Humphrey Field Analyzer 2 (Carl Zeiss, Meditec Inc.) in both eyes. The tests showed superior and inferior visual field loss in OD and superior field loss in OS, as shown in Tables 1 and 2. The results matched the optic disc appearance and RNFL OCT findings. Given the above findings, the patient was referred to the ophthalmologist for a second opinion and management. Subsequently, the patient had been under the continuing care of the ophthalmologist for the following 17 years.

Table 1: Changes in Visual Field from 2005 to 2023 of the Right Eye

Date	Grey Tone	Threshold (dB)	Total Deviation	Pattern Deviation	
29/10/2005					MD: -7.79 dB P<0.5% PSD: 11.33dB P<0.5% GHT: Outside normal limits
11/11/2005					MD: -6.01dB P<0.5% PSD: 11.96dB P<0.5% GHT: Outside normal limits
09/02/2007					MD: -5.83dB P<0.5% PSD: 11.30dB P<0.5% GHT: Outside normal limits
15/02/2008					MD: -5.35dB P<0.5% PSD: 9.30dB P<0.5% GHT: Outside normal limits
26/07/2013					MD: -7.34dB P<0.5% PSD: 11.37dB P<0.5% GHT: Outside normal limits VFI: 83%
13/06/2016					MD: -6.38dB P<0.5% PSD: 11.90dB P<0.5% GHT: Outside normal limits VFI: 83%







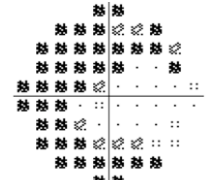


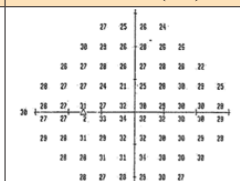
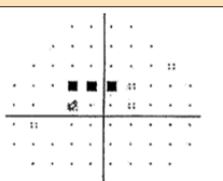
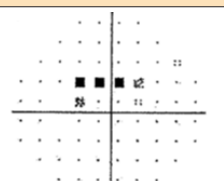
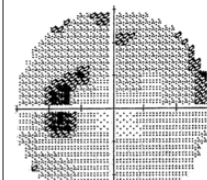






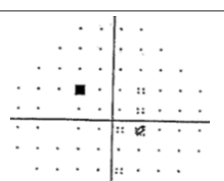








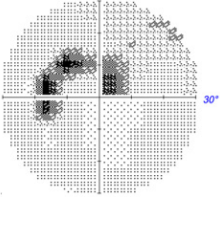
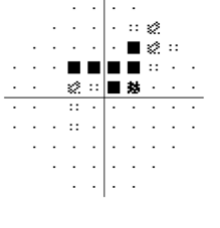
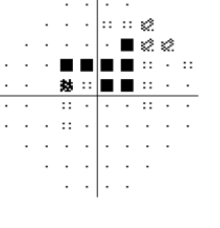
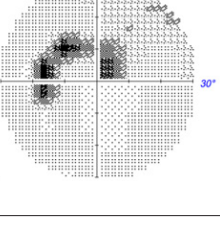
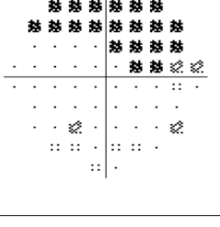

29/03/2023					MD: -8.78dB P<0.5% PSD: 10.78dB P<0.5% GHT: Outside normal limits VFI: 76%
29/3/2023					MD 10-2: -16.30dB P<1% PSD 10-2: 14.76dB P<1%

Table 2: Changes in Visual Field from 2005 to 2023 of the Left Eye

Date	Grey Tone	Threshold (dB)	Total Deviation	Pattern Deviation	
29/10/2005					MD: -1.27 dB PSD: 2.67dB P<10% GHT: Outside normal limits
09/02/2007					MD: -4.00DB P<2% PSD: 3.24dB P<5% GHT: Outside normal limits
15/02/2008					MD: -3.11dB P<2% PSD: 2.24dB GHT: borderline
26/07/2013					MD: -2.44dB P<5% PSD: 3.74dB P<2% GHT: Outside normal limits VFI: 95%
13/06/2016					MD: -1.26dB PSD: 4.99dB P<0.5% GHT: Outside normal limits VFI: 95%

29/03/2023		<pre> 27 24 24 22 29 26 26 23 22 20 28 28 27 27 26 20 23 21 29 29 29 <0 12 15 23 26 27 21 28 31 0 26 29 6 27 28 27 24 30 29 4 28 31 32 31 29 29 27 29 30 31 28 31 31 30 30 29 30 28 30 30 30 31 30 29 28 29 30 30 30 29 28 31 29 29 28 </pre>			MD: -2.70dB P<2% PSD: 7.05dB P<0.5% GHT: Outside normal limits VFI: 87%
29/3/2023		<pre> <0 <0 0 0 <0 <0 23 4 14 <0 <0 11 26 29 32 33 32 11 0 10 18 29 33 34 35 33 32 25 16 27 26 31 32 33 35 33 34 33 33 30 39 32 33 33 33 33 31 32 32 30 30 28 30 32 31 30 27 28 29 30 29 29 31 28 </pre>			MD 10-2: -7.91dB P<1% PSD 10-2: 11.94dB P<1%

Visits at the Ophthalmologist’s Clinic

The patient had 5 follow-ups at the ophthalmologist’s clinic from 2005 to 2016. Her unaided VA in each eye was 6/6, and the IOP ranged from 12 to 18mmHg in OD and 12 to 19mmHg in OS over the years. Visual fields were performed in the follow-ups as presented in Tables 1 and 2. She had been under observation and no treatment had been initiated.

Last Visit

The patient was invited back to serve as a subject in a glaucoma project at the School of Optometry Research Clinic and received a comprehensive eye examination in 2023. She reported to have occasional follow-ups at the ophthalmologist’s clinic and was not on any treatment for NTG. She stated that she had no obvious visual complaint in her daily life. Her general health was unremarkable with no blood pressure issues and she was not under any medication. Her habitual unaided distance VA was OD 6/6+ and OS 6/4.8-. Her best corrected VA was OD 6/4.8- (+0.25/-0.50x75) and OS 6/4.8 (+0.25/-0.75x5). Colour vision tested with ISHIIHARA’s Tests for colour deficiency 24 plates (Edition 1998) was normal in OD and OS. Contrast sensitivity measured by Pelli-Robson contrast sensitivity chart (HAAG-STREIT UK) was within normal limits in each eye. External ocular health revealed moderate superficial punctate keratopathy, moderate nuclear sclerosis, as well as cortical cataracts in both eyes.

IOP measured by NCT with non-contact tonometer NT-530P (NIDEK) was OU 16mmHg; IOP measured by Goldmann Tonometry with AT-1 Applanation tonometer (TAKAGI SEIKO CO., LTD) was OD 15mmHg and OS 17mmHg. CCT measured with non-contact tonometer NT-530P (NIDEK) was OD 552µm and OS 551µm. Anterior chamber angles examined by gonioscopy revealed posterior trabecular meshwork in the nasal and temporal quadrants, scleral spur in the superior quadrant, and ciliary body band in the inferior quadrant in OD. In OS, gonioscopy revealed posterior trabecular meshwork in all four quadrants. No other abnormalities were detected at the anterior chamber angles in both eyes. Internal ocular examination of the posterior pole showed optic discs C/D ratios of 0.85 in both eyes. Drusen were found scattering in the macular regions of both eyes, indicating mild age-related macular degeneration. The fundus photos taken are shown in Figure 1 (OD) and Figure 2 (OS).

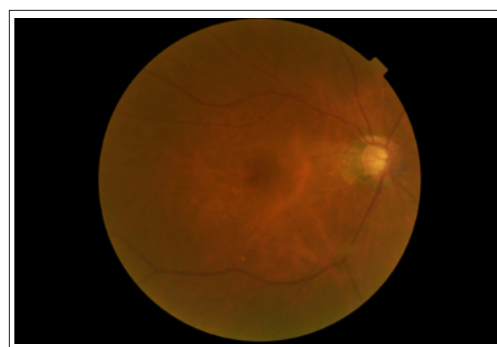


Figure 1: Fundus Photo of the Right Eye (OD) taken in 2023

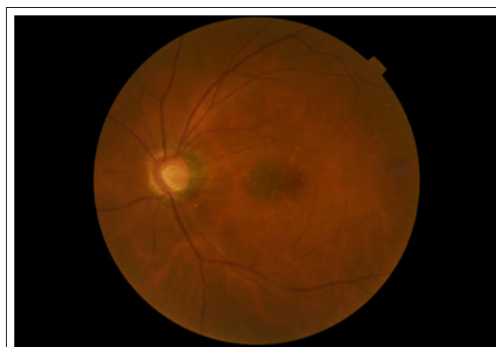

Figure 2: Fundus Photo of the Left Eye (OS) taken in 2023.

Given the history of NTG, automated perimetry, macular and RNFL OCT were performed in this visit.

Visual Field

Automated perimetry with 30-2 SITA fast and 10-2 SITA standard protocols with the Humphrey Field Analyzer 3 (Carl Zeiss, Meditec Inc.) was performed in both eyes. In OD, Glaucoma Hemifield Test (GHT) indicated outside normal limits. Arcuate defects in inferior field extending to the superior hemisphere was revealed with Mean Deviation (MD) of -8.78dB. In OS, GHT also indicated outside normal limits, with arcuate visual field defects extending from the blind spots to the superior nasal field near the central region. MD was -2.70dB. Due to the possible central involvement demonstrated by the depressed points in the central field in 30-2 SITA fast testing in both eyes, 10-2 SITA standard testing was performed. In OD, arcuate defect affecting from the superior nasal to the inferior nasal field was revealed. In OS, arcuate defect in the superior region was shown. As indicated in Tables 1 and 2, the






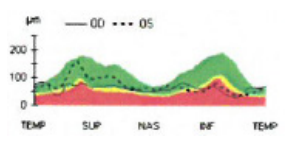
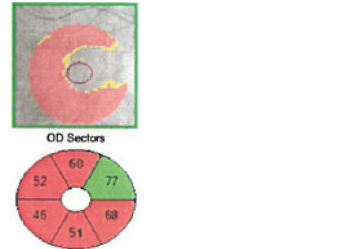
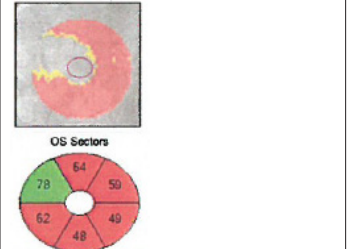
visual field defects demonstrated slow progression over the years.

Optical Coherence Tomography

RNFL OCT was performed with Cirrus HD-OCT model 5000 (Carl Zeiss, Meditec) to examine the RNFL layer thickness, which might explain the patient's visual field defects. OD was shown to be outside normal limits with significant inferior and moderate superior thinning in the RNFL analysis. This matched the considerable inferior field loss extending to the superior field

found in the 30-2 visual field. OS was also shown to be outside normal limits with significant inferior thinning, which matched the superior field loss demonstrated in the visual field. Ganglion Cell Analysis (GCA) found general thinning of ganglion cell layer in both eyes, but this was more significant in the inferior quadrant, matching the findings in the RNFL analysis and 10-2 visual field. Although there was a decrease in RNFL thickness, the changes were slow over the years, as shown in Table 3.

Table 3: Optical Coherence Tomography (OCT) Findings of the Right Eye (OD) and the Left Eye (OS) from 2005 to 2023

Date	OD		OS		Comparison between OD and OS									
	Average retinal Nerve Fibre Layer (RNFL) thickness		Average Retinal Nerve Fibre Layer (RNFL) thickness											
29/10/2005 Zeiss Stratus OCT RNFL	86.4 µm		97.75 µm											
29/3/2023 Zeiss Cirrus OCT RNFL	63 µm		74 µm											
29/3/2023 Zeiss Cirrus OCT Ganglion Cell Analysis (GCA)					<table border="1"> <thead> <tr> <th></th> <th>OD µm</th> <th>OS µm</th> </tr> </thead> <tbody> <tr> <td>Average GCL + IPL Thickness</td> <td>59</td> <td>60</td> </tr> <tr> <td>Minimum GCL + IPL Thickness</td> <td>45</td> <td>47</td> </tr> </tbody> </table>		OD µm	OS µm	Average GCL + IPL Thickness	59	60	Minimum GCL + IPL Thickness	45	47
	OD µm	OS µm												
Average GCL + IPL Thickness	59	60												
Minimum GCL + IPL Thickness	45	47												

Discussion

The patient in this case shows that the progression rate of untreated NTG can be very slow. This suggests that it may not be necessary to take immediate action to treat the condition once it is diagnosed [21]. Factors including life expectancy of the patients, severity and rate of progression of NTG, effects on vision-related quality of life such as reading, mobility and driving, and possible adverse effects of the treatment should be considered before deciding if treatment must be initiated [12,22]. However, NTG can also progress quickly enough that MD deterioration reaches -2dB/year in visual field, resulting in possibly disturbing outcomes [21]. Therefore, close monitoring of the condition is recommended. This can be achieved by taking six visual fields with good baseline in the first two years, to screen out fast progressors with MD deterioration of -2dB/year [23].

The patient in this case was diagnosed to have NTG 17 years ago. We noted that, in OD, the MD in the first visual field performed in our clinic was different from the second visual field performed in the ophthalmologist's clinic about two weeks later. Therefore, changes of dB/year are both presented with reference to both baselines. The progression in visual field loss was -0.06dB/year (compared with the MD on 28/10/2005) and -0.16dB/year (compared with the MD

on 11/11/2005) in OD and -0.08dB/year in OS. At this rate of visual field loss progression, it would seem that she would maintain her functional vision for the rest of her life. The progression in RNFL thickness was -1.38 µm/year in OD and -1.4 µm/year in OS. The rate of progression in terms of visual field defects was slow, and the progression in RNFL was moderate with reference to the previously defined criteria [14–16]. The visual field progression in OS might be age-related, as it was even slower than the expected progression rate of -0.102dB/year after 53.4 years old [17]. Nevertheless, the visual field loss might threaten fixation, and therefore close monitoring was still required despite the very slow NTG progression without treatment.

Conclusions

This case illustrated the natural history of untreated NTG in an extended follow-up period of 17 years. Based on the clinical findings, no medication and surgery were found to be necessary. Continual monitoring of visual function and ocular health of this patient with regular comprehensive eye examination is recommended. More cases are warranted for a deeper understanding of NTG management.

Acknowledgement: GCW was partially supported by Inno HK initiative and the Hong Kong SAR Government.

Statement of Ethics: Written informed consent has been obtained from the subject discussed in this case report.

Conflict of Interest: There are no financial conflicts of interest to disclose.

Funding Sources: China Optometric Education Fund of The Hong Kong Polytechnic University (8397) and InnoHK initiative and the Hong Kong SAR Government.

References

1. Leung DY, Tham CC (2022) Normal-tension glaucoma: Current concepts and approaches-A review. *Clin Experiment Ophthalmol* 50: 247-259.
2. Kim CS, Seong GJ, Lee NH, Song K, Namil Study Group, Korean Glaucoma Society (2011) Prevalence of primary open-angle glaucoma in central South Korea the Namil study. *Ophthalmology* 118: 1024-1030.
3. Komori S, Ishida K, Yamamoto T (2014) Results of long-term monitoring of normal-tension glaucoma patients receiving medical therapy: results of an 18-year follow-up. *Graefes Arch Clin Exp Ophthalmol* 252: 1963-1970.
4. Trivli A, Koliarakis I, Terzidou C, Goulielmos GN, Siganos CS, et al. (2019) Normal-tension glaucoma: Pathogenesis and genetics. *Exp Ther Med* 17: 563-574.
5. Vaghefi E, Shon C, Reading S, Sutherland T, Borges V, et al. (2021) Intraocular pressure fluctuation during resistance exercise. *BMJ Open Ophthalmol* 6: e000723.
6. Jiménez R, Vera J (2018) Effect of examination stress on intraocular pressure in university students. *Appl Ergon* 67: 252-258.
7. Noya-Padin V, Pena-Verdeal H, Nores-Palmas N, Giraldez MJ, Yebra-Pimentel E (2024) Intraocular pressure fluctuations assessment in professional wind instrument players. *Clin Exp Optom* 9: 1-6.
8. Kim KE, Park KH (2016) Update on the Prevalence, Etiology, Diagnosis, and Monitoring of Normal-Tension Glaucoma. *Asia-Pac J Ophthalmol* 5: 23-31.
9. Kamal D, Hitchings R (1998) Normal tension glaucoma--a practical approach. *Br J Ophthalmol* 82: 835-840.
10. Hitchings RA (1992) Low tension glaucoma--its place in modern glaucoma practice. *Br J Ophthalmol* 76: 494-496.
11. Woo SJ, Park KH, Kim DM (2003) Comparison of localised nerve fibre layer defects in normal tension glaucoma and primary open angle glaucoma. *Br J Ophthalmol* 87: 695.
12. No authors (1998) Comparison of glaucomatous progression between untreated patients with normal-tension glaucoma and patients with therapeutically reduced intraocular pressures. Collaborative Normal-Tension Glaucoma Study Group. *Am J Ophthalmol* 126: 487-497.
13. Vianna JR, Danthurebandara VM, Sharpe GP, Hutchison DM, Belliveau AC, et al. (2015) Importance of Normal Aging in Estimating the Rate of Glaucomatous Neuroretinal Rim and Retinal Nerve Fiber Layer Loss. *Ophthalmology* 122: 2392-2398.
14. Celebi ARC, Mirza GE (2013) Age-related change in retinal nerve fiber layer thickness measured with spectral domain optical coherence tomography. *Invest Ophthalmol Vis Sci* 54: 8095-8103.
15. Lee JY, Hwang YH, Lee SM, Kim YY (2012) Age and Retinal Nerve Fiber Layer Thickness Measured by Spectral Domain Optical Coherence Tomography. *Korean J Ophthalmol* 26: 163-168.
16. Jammal AA, Thompson AC, Mariottoni EB, Urata CN, Estrela T, et al. (2021) Rates of Glaucomatous Structural and Functional Change from a Large Clinical Population: The Duke Glaucoma Registry Study. *Am J Ophthalmol* 222: 238-247.
17. Spry PG, Johnson CA (2001) Senescent changes of the normal visual field: an age-old problem. *Optom Vis Sci* 78: 436-441.
18. Chauhan BC, Malik R, Shuba LM, Rafuse PE, Nicoleta MT, et al. (2014) Rates of Glaucomatous Visual Field Change in a Large Clinical Population. *Invest Ophthalmol Vis Sci* 55: 4135-4143.
19. Heijl A, Buchholz P, Norrgren G, Bengtsson B (2013) Rates of visual field progression in clinical glaucoma care. *Acta Ophthalmol* 91: 406-412.
20. Han JC, Han SH, Park DY, Lee EJ, Kee C (2020) Clinical Course and Risk Factors for Visual Field Progression in Normal-Tension Glaucoma with Myopia Without Glaucoma Medications. *Am J Ophthalmol* 209: 77-87.
21. Anderson DR, Drance SM, Schulzer M, Collaborative Normal-Tension Glaucoma Study Group (2001) Natural history of normal-tension glaucoma. *Ophthalmology* 108: 247-253.
22. Saunders LJ, Medeiros FA, Weinreb RN, Zangwill LM (2016) What rates of glaucoma progression are clinically significant? *Expert Rev Ophthalmol* 11: 227-234.
23. Chauhan BC, Garway-Heath DF, Goñi FJ, Rossetti L, Bengtsson B, et al. (2008) Practical recommendations for measuring rates of visual field change in glaucoma. *Br J Ophthalmol* 92: 569-573.

Copyright: ©2024 George C Woo, et al. This is an open-access article distributed under the terms of the Creative Commons Attribution License, which permits unrestricted use, distribution, and reproduction in any medium, provided the original author and source are credited.