

## Case Report

## Open Access

## Rehabilitation Journey-Vision Recovery in Acquired Strabismus Following Post-Traumatic Retinal Detachment

Rajeev Prasad<sup>1\*</sup> and Sumon Kumar Sarkar<sup>2</sup><sup>1</sup>MCOptom, FLVPEI (Low Vision), Consultant Optometrist, Director, Visual Eyez, India<sup>2</sup>BOptom, Optometrist, Visual Eyez, India**ABSTRACT**

**Background:** This case report examines the rehabilitation of a 21-year-old male with acquired strabismic amblyopia and permanent retinal alterations following childhood trauma and retinal detachment surgery, a scenario rarely documented in ophthalmic literature. The patient's complex presentation—marked by severe vision loss, constant exotropia, and suppression—highlights the challenges of restoring functional vision in post-traumatic cases with structural damage.

**Case Presentation:** Initial evaluation revealed right-eye visual acuity of 2/60, exotropia of 45 prism diopters, and absent stereopsis, alongside a macular hole and peripheral vision loss (VFI: 66%). A structured, three-phase vision therapy protocol was implemented: 1) Monocular therapy (foveal tagging, Ambi-iNET, SVI Rotator, MIT-2) to stabilize fixation and enhance oculomotor control; 2) Anti-suppression training (MFBF, Red-Blue Binocular Reading, Brock string) to promote binocular integration; and 3) Binocular vergence therapy (HoloLens VTS4, Tranaglyph cards, Syntonics) to refine sensory and motor fusion.

**Results:** After 116 in-office sessions, visual acuity improved to 6/18, exotropia reduced to 6–8 prism diopters, and stereopsis emerged at 200 seconds of arc. Oculomotor metrics via HoloLens VTS4 demonstrated 91% saccadic and 94% pursuit accuracy, while NPC improved to 14/17 cm. Functional gains included enhanced comfort during computer use and newfound ability to perceive 3D media.

**Conclusion:** This case challenges conventional prognostic assumptions by demonstrating significant functional recovery despite irreversible retinal damage. The success of the multimodal approach—integrating traditional techniques with immersive technologies—underscores the potential of tailored vision therapy to restore binocularity and quality of life in complex post-traumatic cases. These findings advocate for expanded research into structured rehabilitation protocols for patients with similar structural and functional deficits.

**\*Corresponding author**

Rajeev Prasad, MCOptom, FLVPEI (Low Vision), Consultant Optometrist, Director, Visual Eyez, India.

**Received:** May 09, 2025; **Accepted:** May 15, 2025; **Published:** May 23, 2025**Background**

Retinal detachment, which is the separation of the neurosensory retina from the underlying pigment epithelium, can have various causes. Nevertheless, the most prevalent form is rhegmatogenous retinal detachment, which occurs after one or more retinal breaks. A majority of eyes with this type of detachment have retinal breaks that arise spontaneously; nonetheless, a small percentage of cases are caused by trauma. Rhegmatogenous retinal detachment, often referred to as retinal detachment, is a severe condition that can result in blindness, with an incidence rate of approximately 1 in 10,000 adults per year [1-3]. Traumatic retinal breaks are characterized by a distinct shape that varies depending on the nature of the ocular injury [4]. Impact of a blunt object against the eye causes direct tissue damage at the site of impact and indirect injury to distant intraocular tissues by transmitted forces. Contusional trauma is widely acknowledged as a significant cause of rhegmatogenous retinal detachment, as evidenced by Eagling's report, which indicates that this type of injury accounts for 4-6% of all cases [5].

Retinal Detachment (RD) is a common cause of ophthalmic emergency that typically requires prompt surgical intervention to prevent visual impairment [6]. Visual recovery after macula-off retinal detachment Approximately 60% of patients in all three groups regained 20/50 or better vision, with 35% regaining 20/60 to 20/200 vision, and 5% having less than 20/400 vision [7]. Loss of Visual Acuity after Successful Surgery for Macula-On RD around 15% after successful surgery [8]. However, like any surgery, it can have potential complications. One such complication is strabismus.

Strabismus after retinal detachment surgery is temporary in most cases. Long-term strabismus, however, is seen in 5% to 25% of patients. In most cases the cause is restrictive strabismus due to adhesions, muscle fibrosis, or scarring involving the buckling material. Deviations due to direct muscle injury and "sensory" deviations due to poor vision also occur [9]. Rainin and Carlson had reported in 1985 that experimental injection of 0.75% bupivacaine (Marcaine) into human extraocular muscles at the time of surgery often produced postoperative strabismus [10].

### Case Report

A 21-year-old male presented with complaints of squint (eye turn) and of poor vision in the right eye. History indicated that the patient had blunt trauma to the right eye at the age of 6 years. This was treated with reattachment surgery performed elsewhere.

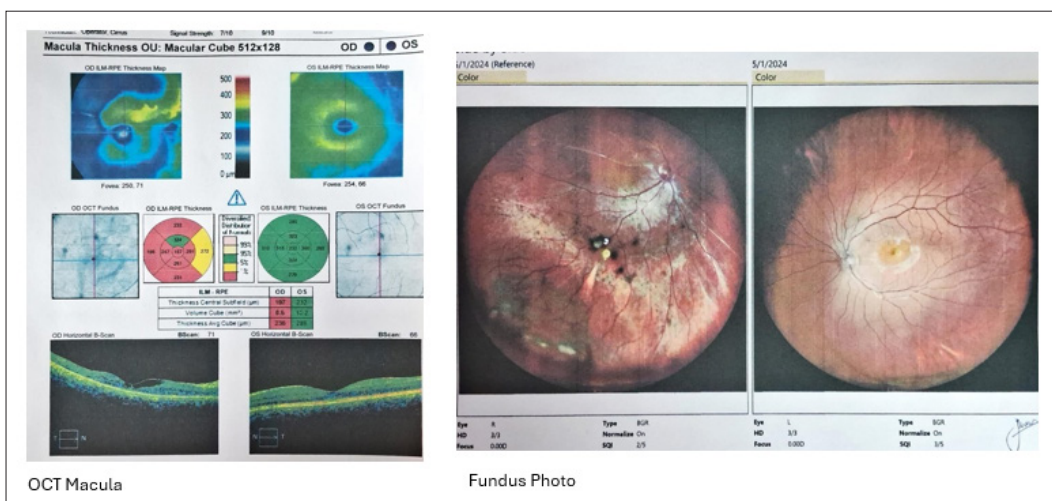
### Initial Examination

Upon initial assessment, the patient's unaided visual acuity measured 2/60 in the right eye, with near vision of N36, and 6/6 in the left eye, with near vision of N6. The objective refraction revealed no subjective acceptance in the right eye.

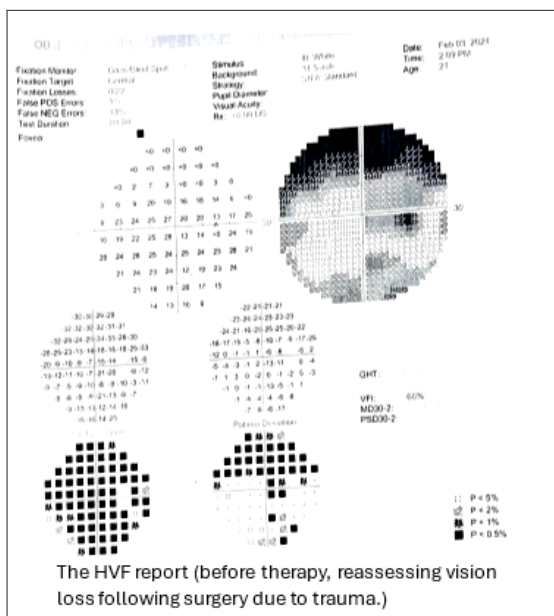
The evaluation of strabismus demonstrated a manifest exotropia of 45 prism diopters. Moreover, the Worth Four Dot sensory test revealed the suppression of the right eye at both near and distance. The findings of the visuoscopy test demonstrated that the right eye exhibited an unsteady temporal eccentric fixation of 2-4 prism diopters. The Titmus fly stereo test revealed the absence of stereopsis. Extraocular motility was unrestricted monocularly. The VTS4 HoloLens Assessment tool revealed reduced saccades and

pursuits of the right eye. According to the results outlined above, the patient was diagnosed with acquired strabismic amblyopia resulting from post-traumatic ocular complications. Despite being advised to undergo vision therapy, the prognosis for improvement was cautiously explained.

The patient was recommended to undergo the Optical Coherence Tomography (OCT) macula test along with the Humphrey Visual Field (HVF) test to assess his surgical history and determine any relevant changes in macular structure and visual field integrity. Coherence Tomography (OCT) and fundus photography collectively provide a detailed view of the current state of the right eye (OD). The OCT imaging reveals that, subsequent to the reattachment surgery, a segment of the retina, which includes the macula, remains partially detached, as evidenced by the existence of a full-thickness macular hole. The results obtained from the fundus photographs align with these observations, portraying modifications in the Retinal Pigment Epithelium (RPE), scarring, and laser photocoagulation marks, which are all indicative of the surgical repair procedures that have been implemented.



The Humphrey Visual Field (HVF) report shows significant peripheral vision loss in the Right eye, indicated by widespread depressed areas, particularly superiorly and nasally. The Visual Field Index (VFI) was 66%, suggesting moderate visual field impairment. Mean Deviation (MD) is -10.2 dB, and Pattern Standard Deviation (PSD) is 10.2 dB, indicating a non-uniform loss likely due to glaucomatous damage. The Glaucoma Hemifield Test (GHT) result is outside normal limits.



## Treatment Process

The patient's treatment plan was structured around three key objectives arranged in order of significance. These objectives aimed to expand the patient's visual field, improve visual ability, and enhance ocular motility.

In the management of amblyopia associated with strabismus, three distinct phases comprise the therapeutic intervention. The primary aim of the initial phase is to enhance monocular functions, such as saccades, pursuits, accommodation, ocular motility, form recognition, and perceptual discrimination. This phase establishes the fundamental skills necessary for more intricate visual processing.

In the intermediate stage, the emphasis was placed on Monocular Fixation in a Binocular Field (MFBF) and binocular exercises. These interventions were intentionally developed to promote visual processing within a binocular setting, which is essential for the effective integration of visual information from both eyes.

In the final stage of treatment, the emphasis was placed on developing binocular and intersensory integration. This phase aimed to consolidate the gains from earlier stages and to foster a more integrated sensory experience. For the patient with strabismic amblyopia, prolonged engagement in the MFBF phase was crucial, as it addressed the specific challenges posed by strabismus, including the alignment and coordination between the eyes. This structured, phase-wise approach was instrumental in achieving the therapeutic goals and enhancing the patient's visual outcomes.

### Initial Phase

#### Monocular Therapy

##### Gross Motor Therapy

The initial phase concentrated on monocular gross oculomotor functions, employing specific exercises to enhance visual skills. These included balancing while performing Hart Chart saccades to improve rapid and accurate eye movements; executing Marsden ball pursuits to stabilize and enhance smooth pursuit movements; performing rotations on a standing rotator to challenge the vestibulo-ocular reflex, thereby maintaining visual stability during movements; demonstrating peripheral awareness to better perceive and react to the wider visual field; and maintaining balance while playing catch with a ball, integrating dynamic hand-eye coordination and balance in real-world scenarios.

#### Oculomotor Therapy

The main objective of this phase was to improve monocular visual abilities in the amblyopic eye, particularly in saccades, pursuits, central fixation, and overall vision and functional visual field. We implemented a particular fixation therapy known as foveal tagging. This technique was specifically applied to the amblyopic eye, aimed at improving foveal awareness and fixation stability. The method involved the patient focusing on a brief, intense flash of light, varying in intensity from 100 to 300 cd/m<sup>2</sup> and lasting for a duration of 100 to 500 milliseconds, repeated 8 to 10 times each day, twice a day. After blinking, the patient was instructed to project the resulting afterimage onto a flat surface, such as a wall or tabletop.

This exercise has a multitude of therapeutic benefits. Firstly, it assists in strengthening the patient's capacity to maintain visual focus with the amblyopic eye. Secondly, it enhances the stability of foveal fixation. Lastly, it reinforces the neural connections between the fovea and the brain. By repeatedly performing the

task of projecting the afterimage onto various surfaces, the patient is able to better manage and utilize the visual abilities of the amblyopic eye.

We also utilized the Amb-iNET system, a specialized software designed to treat oculomotor dysfunctions. The therapeutic plan was carefully devised to specifically target and enhance saccadic and pursuit eye movements, which are essential for effective visual tracking and coordination. This approach was integral in facilitating the targeted rehabilitation of these essential visual functions, thereby significantly improving the patient's visual performance. The subject completed a series of exercises utilizing the Amb-iNET system, which has been specifically developed for the purpose of training and rehabilitating eye movements. These exercises required the patient to make rapid and accurate shifts in gaze to fixed targets (saccades) and to smoothly follow the trajectory of moving objects (pursuits).

The use of Modified Hart Chart with crowding bars was implemented to improve fixation and address the crowding effect. To achieve this, the Hart Chart was modified by increasing the spacing between the letters, resulting in reduced visual interference and enhanced visual clarity. This modification permitted the patient to focus more effectively on each character and stabilize their gaze, unencumbered by the distraction of adjacent letters. This tailored intervention significantly improved the patient's ability to shift attention across the visual field, thereby enhancing visual acuity and the functional visual field.

The Fast-Pointing Method applied through the Sanet Vision Integrator was utilized to address the eccentric fixation of the amblyopic eye using a targeted approach. This method involved the Rotator module, where the patient was instructed to touch rotating targets rapidly. The duration of each session was set at 10 minutes. However, over the course of 30 sessions, the interval was systematically reduced to 2 minutes, simultaneous with a reduction of the target size.

After finishing these sessions, further enhancement of foveal fixation in the right eye was pursued through the use of the Macular Integrity Tester-2 (MIT-2). Alongside these methods, we also implemented a suite of therapies aimed at enhancing oculomotor control, focusing on refining saccades and pursuits. These therapies incorporated the use of the SVI saccades module, Modified Hart Chart, Marsden ball, HoloLens VTS4 based auto saccades and pursuits each contributing to the overall stabilization and accuracy of the patient's ocular movements.

After the completion of 45 sessions of office-based vision therapy, a progress evaluation was conducted to obtain detailed measurements. Patient's best corrected visual acuity in amblyopic eye was 6/48 from 2/60 for distance and N12 for near. His fixation behavior through the amblyopic eye was improved. Pursuits and saccades were normalized in the right eye. On cover testing, his exotropia reduced to 20 prism diopters at distance and near. The patient was advised to continue vision therapy for 30 days more.

### Intermediate Phases

In the second phase of in-office vision therapy treatment, our primary clinical goal was to reduce the suppression in the right eye and reduce the magnitude of strabismus to promote binocularity.

Anti-suppression training was conducted using a comprehensive therapy plan that included a variety of targeted strategies to improve

ocular alignment and minimize visual suppression. In this stage of the vision therapy program, we focused on reducing visual suppression and enhancing ocular alignment through a targeted approach using Monocular Fixation in a Binocular Field (MFBF) therapy, facilitated by the Sanet Vision Integrator (SVI) module with Red-Blue Filter. This therapy was specifically designed to encourage the use of both eyes simultaneously by presenting the weaker eye with a clear target within a binocular field, while the stronger eye received a less distinct background. This setup was integral to training the visual system to decrease the dominance of the stronger eye and improve the functional integration of the weaker eye into overall vision. The use of the SVI module enabled precise control over the visual stimuli, allowing for designed therapy sessions that directly addressed the individual needs of the patient, leading to reduced suppression and visual coordination. This technique was specifically designed to reduce the suppression of the weaker eye by encouraging simultaneous input from both eyes, thus enhancing binocular integration and improving visual coordination.

The Red-Blue Binocular Reading technique with red-blue filter, using the Dynamic Reader iNet software from Home Therapy Solutions (HTS), was incorporated into the therapy. This specific module involved the patient engaging in reading tasks on a computer display, where the colors of the text red, green, and orange—were randomly distributed over the paragraph. The distinct visual inputs provided by each differently colored section of text stimulate the brain to integrate these separate images into a single cohesive view. This method is particularly effective in combating suppression, where one eye may dominate the visual perception to the exclusion of the other. By providing each eye with its unique stimulus, the Dynamic Reader iNet's Red-Blue Binocular Reading module forces the use of the suppressed eye, thus promoting equal visual input from both eyes. Additionally, we performed the Brock string exercise, a traditional and effective tool reducing suppression and improving ocular alignment. This exercise involves focusing on beads at various points along a string, which the patient must align with their line of sight, thereby facilitating the development of precise visual alignment and binocular cooperation.

In the eye alignment therapy segment of our treatment protocol, we implemented a specialized fixation therapy to enhance binocular coordination. This innovative method involved flashing a horizontal line to one eye and a vertical line to the other eye sequentially. The patient was then instructed to mentally combine these after images to form a cohesive 'plus' sign, a process that trains the brain to integrate disparate visual inputs into a unified perception.

This specific approach was tailored to address the challenges associated with exotropia, promoting improved collaboration between the eyes. Successfully merging the horizontal and vertical flashes into a single image is indicative of enhanced binocular function and an improvement in ocular alignment.

Furthermore, the Life Saver card was utilized to enhance the patient's converging ability. This exercise focuses on increasing the patient's control over their eye convergence through repeated practice, essential for tasks requiring near vision and for improving overall binocular function.

Following 36 additional in-office vision therapy sessions, the patient's visual acuity improved to 6/30. On the day of assessment, a subjective refraction was performed, which revealed that while the patient accepted the prescription, it did not result in further enhancement of visual acuity. Concurrently, the patient experienced

diplopia, as indicated by the outcomes of the Worth 4 Dot test at both distance and near settings, suggesting ongoing challenges with binocular vision integration.

The cover test, revealed a significant ocular misalignment with a deviation of 15 prism diopters. Despite this deviation, there was a notable improvement in the patient's ocular motor functions. This was particularly evident in the results from the VTS HoloLens RDS Vergence module, which showed substantial improvements in the patient's ability to fixate accurately. These findings underscore the complexity of the patient's condition, highlighting both the challenges and achievements. The improvements in fixation are particularly encouraging, indicating that visual therapy has effectively strengthened the neuromuscular control of the eyes, an essential aspect for achieving more stable and coherent visual processing. This mixed outcome illustrates the multifaceted nature of vision therapy, where significant advances in certain areas may occur alongside persistent difficulties in others.

### **The Final Phase**

In the final stage, our focus was on improving vergence range and enhancing binocular coordination. To achieve this, we utilized the VTS4 module with the HoloLens to create an immersive environment that allowed for precise vergence exercises. Our aim in using this technology was to improve the patient's capacity to dynamically converge and diverge their eyes, crucial for enhancing binocular coordination and focus on different distances. In addition, we employed computerized vergence therapy, which involves a set of specific exercises intended to systematically improve the patient's eye coordination and focus. The objective was to progressively enhance the patient's vergence abilities, thereby improving their ability to manage visual demands at different depths.

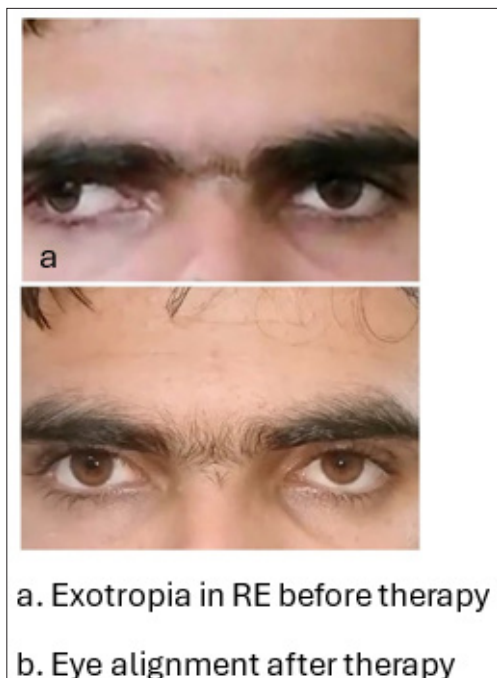We also incorporated Bernell Tranaglyph BC 500 and BC 600 series cards to promote sensory fusion by presenting slightly different images to each eye, encouraging the brain to merge these images into a single, cohesive visual perception. The goal was to enhance sensory integration of visual inputs, reduce visual suppression, and foster a unified binocular vision.

Motor fusion exercises were introduced to strengthen and expand the patient's functional range of vergence. These exercises aimed to enhance the mechanical aspects of vergence, improving the robustness of the binocular system and allowing for more effective eye alignment under various conditions. Lastly, we applied Syntonics Therapy using an Alpha-Delta and Mu-delta Filter, a light therapy targeting the photoreceptive systems to support and enhance visual processing.

After completing 29 phase 3 sessions and 116 in-office appointments, a final evaluation showed that the patient's visual acuity in the amblyopic eye (OD) improved to 6/18 from 2/60 for distance and N12 for near vision. The Worth Four Dot Test indicated successful fusion for both distance and near, while a cover test revealed the exotropia had decreased to 6-8 prism diopters. Although the patient was advised to continue home vision therapy for maintenance.

### **Final Result**

During the final evaluation, visual acuity had improved from 2/60 to 6/18 in the right eye (amblyopic eye), which had a history of Trauma and Macular reattachment surgery. His constant right exotropia reduced to 6 pd from 48 pd. Stereoacuity improved to 200 sec of arc from the absence of stereoacuity.



Significant enhancements were observed by the patient while engaged in activities such as playing 3D games and watching 3D movies. These improvements are indicative of the success of the vision therapy protocols implemented, the patient also experienced increased comfort during computer use, which further underscores the efficacy of the therapeutic interventions. The overall positive feedback from the patient and his family highlights the potential for such therapies to improve quality of life. The patient has been advised to continue follow-up visits at our clinic to ensure sustained improvement and monitor any long-term adjustments needed in his treatment plan.

Parameter	Before Therapy	After Therapy
Distance Visual Acuity (Right Eye)	2/60	6/18
Near Vision (Right Eye)	N72	N12
Stereoacuity	ABSENT	200 sec of arc
Near Point of Convergence (NPC)	Not performed (due to the absence of Fixation and eye alignment)	14/17 (cm)
Saccadic (HoloLens VTS4 Tool)	Not performed (due to the absence of Fixation and eye alignment)	91% accurate
Pursuit Accuracy (HoloLens VTS4 Tool)	Not performed (due to the absence of Fixation and eye alignment)	94% accurate

### Discussion

The effectiveness of a vision therapy method that incorporates multiple approaches to enhance visual acuity and binocular vision in a patient with acquired strabismic amblyopia resulting from traumatic retinal detachment and subsequent surgical treatments is demonstrated in this case report. The unique clinical aspect of this case lies in the improvement of the patient's vision and ocular

alignment, despite the presence of extensive retinal alterations, which is not commonly discussed in existing ophthalmic literature. The use of therapeutic interventions in treating retinal changes associated with strabismic amblyopia represents a revolutionary approach, as there are no established precedents for this type of treatment.

Monocular Fixation in Binocular Field (MFBF) therapy and syntonics phototherapy were key components. Syntonics phototherapy, which involves the application of specific light frequencies to stimulate photosensitive elements in the retina and neural pathways, has been shown to improve visual fields and oculomotor functions. It has been found that this type of treatment is beneficial for oculomotor function enhancement and vision improvement. In order to reduce visual suppression, MFBF therapy promotes using the amblyopic eye for central tasks while using both eyes to receive peripheral stimuli. Additionally, the introduction of HoloLens VTS4 allowed for accurate, personalized binocular vision exercises that tailored the treatment to the patient's individual needs.

Improving foveal fixation and stability in the amblyopic eye was the goal of the initial fixation therapies, which were an essential part of the therapy plan. Methods like targeted foveal tagging in which a temporary afterimage is produced by quick, bright flashes were used. With the help of this afterimage training, the patient's amblyopic eye is encouraged to focus intently, improving the accuracy and duration of fixation. Furthermore, the Sanet Vision Integrator (SVI) exercises helped build more precise and steady eye movements, which are essential for enhancing total visual performance.

Comparatively, there aren't many studies in the literature that demonstrate visual improvement in people with strabismic amblyopia, which is the outcome of traumatic retinal detachment and surgery during childhood. Therefore, this case marks a significant contribution to the field. It illustrates how, even in complicated situations, a tailored, technologically advanced strategy may significantly improve functional vision and quality of life. This case inspires further research and implementation of such creative, multimodal treatment approaches, setting an example for the treatment of related illnesses and raising the possibility of a paradigm change in vision therapy.

Initial fixation therapies were essential in treating amblyopia, focusing on enhancing foveal fixation and stability. Techniques like targeted foveal tagging used brief flashes to create a temporary afterimage, encouraging patients to concentrate on the amblyopic eye and improving fixation precision. Additionally, exercises with the Sanet Vision Integrator (SVI) supported the development of stable eye movements, crucial for overall visual function.

### References

- Haimann MH, Burton TC, Brown CK (1982) Epidemiology of Retinal Detachment. Arch Ophthalmol 100: 289-292.
- Törnquist R, Törnquist P, Stenkula S (1987) Retinal detachment: A study of a population-based patient material in Sweden 1971-1981. II. Pre-operative findings. Acta Ophthalmol (Copenh) 65: 223-230.
- Algvere PV, Jahnberg P, Textorius O (1999) The Swedish Retinal Detachment Register. Graefes Arch Clin Exp Ophthalmol 237: 137-144.
- Cooling RJ (1986) Traumatic retinal detachment--mechanisms and management. Trans Ophthalmol Soc U K 105: 575-579.
- Eagling EM (1974) Ocular damage after blunt trauma to

- the eye. Its relationship to the nature of the injury. Br J Ophthalmol 58: 126-140.
6. Mahmoudi S, Almony A (2016) Macula-Sparing rhegmatogenous retinal detachment: Is emergent surgery necessary? J Ophthalmic Vis Res 11: 100.
  7. Ross WH (2002) Visual recovery after macula-off retinal detachment. Eye 16: 440-446.
  8. Di Lauro S, Castrejón M, Fernández I, Rojas J, Coco RM, et al. (2015) Loss of Visual Acuity after Successful Surgery for Macula-On Rhegmatogenous Retinal Detachment in a Prospective Multicentre Study. J Ophthalmol 2015 :1-8.
  9. Farr AK, Guyton DL (2000) Strabismus after retinal detachment surgery. Curr Opin Ophthalmol [Internet] 11: 207-210.
  10. Rainin EA (1985) Postoperative Diplopia and Ptosis: A Clinical Hypothesis Based on the Myotoxicity of Local Anesthetics. Arch Ophthalmol 103: 1337.

**Copyright:** ©2025 Rajeev Prasad. This is an open-access article distributed under the terms of the Creative Commons Attribution License, which permits unrestricted use, distribution, and reproduction in any medium, provided the original author and source are credited.